

# Laser focused?

Clinical atlas for interpreting two  
methods of fundus photography

Assi Nikander, Stefan Skog, Olli Uotila

This atlas features fundus images of two different imaging techniques; the Scanning Laser Ophthalmoscope (SLO) EasyScan and the traditional fundus camera, Canon CX-1.

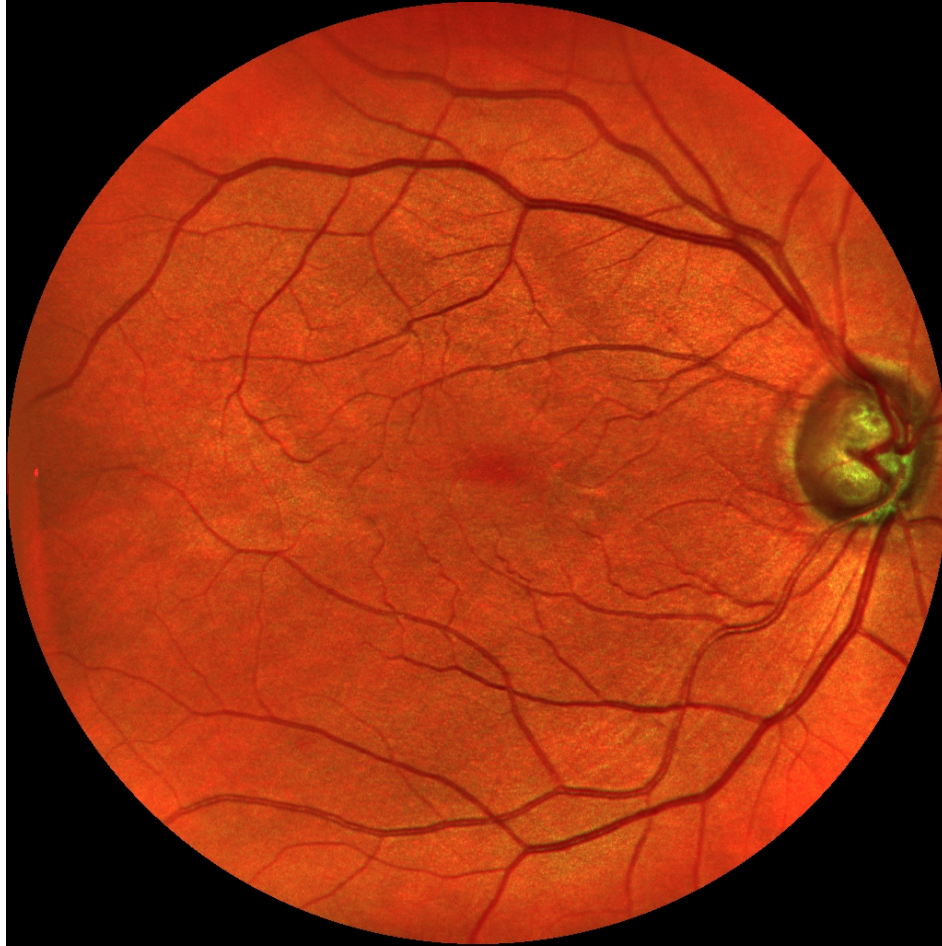Each fundus is photographed in three different modes; colour, green and cobalt (Canon CX-1) alternatively pseudocolour, green and near infrared (EasyScan).

EasyScan images were taken without dilation while Canon images were taken through dilated pupils.

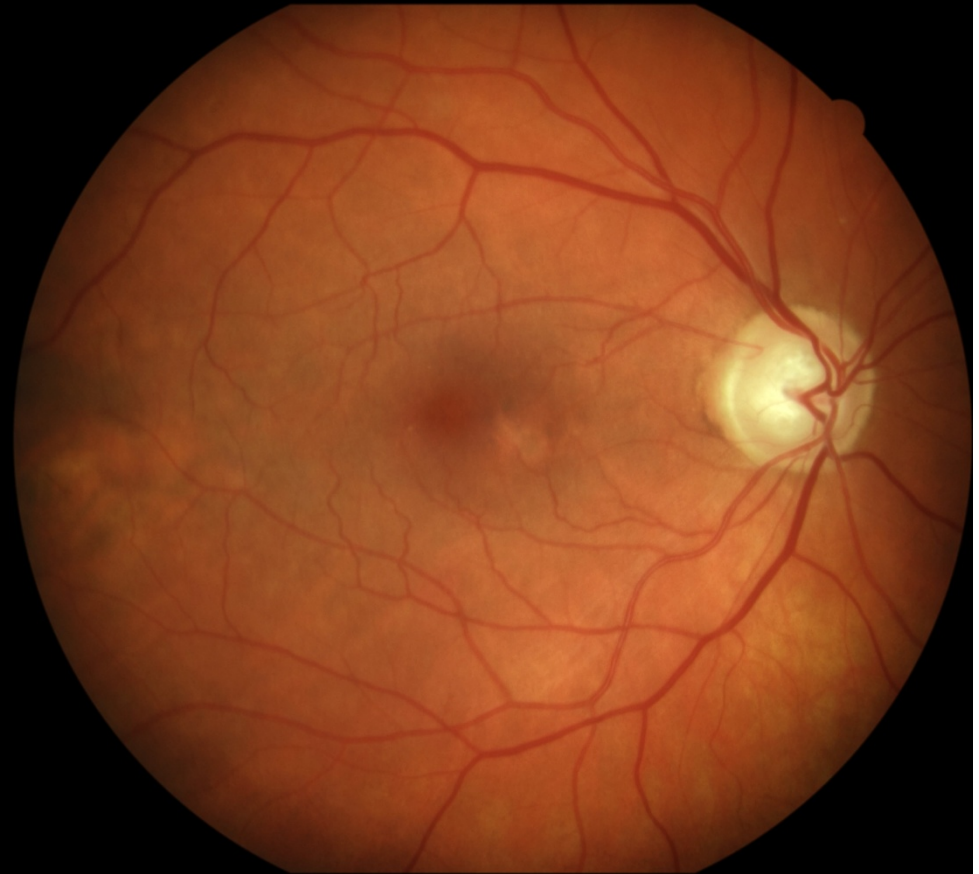

# Male, age 63, glaucoma

EasyScan

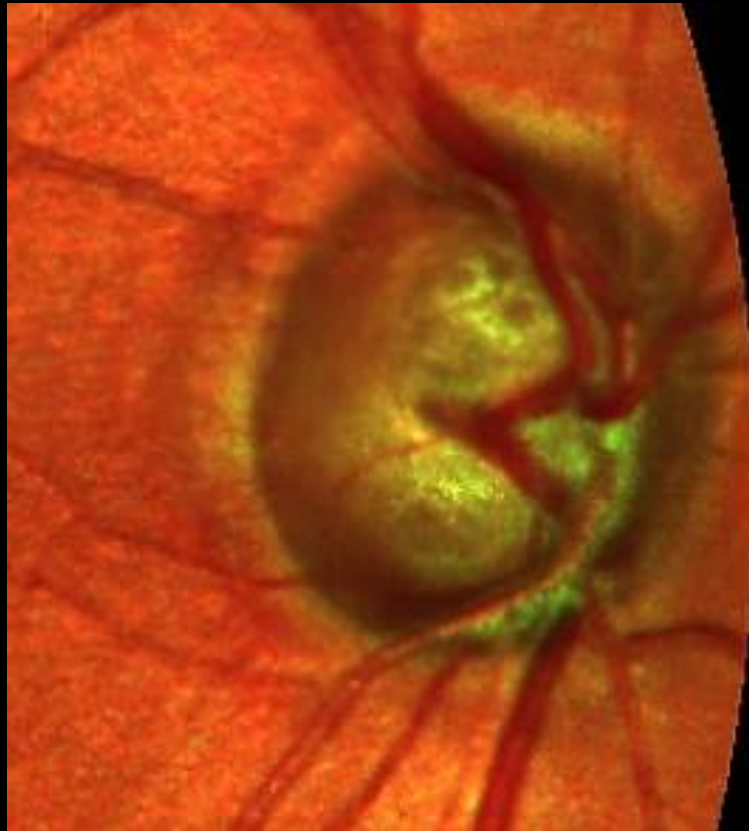

Canon

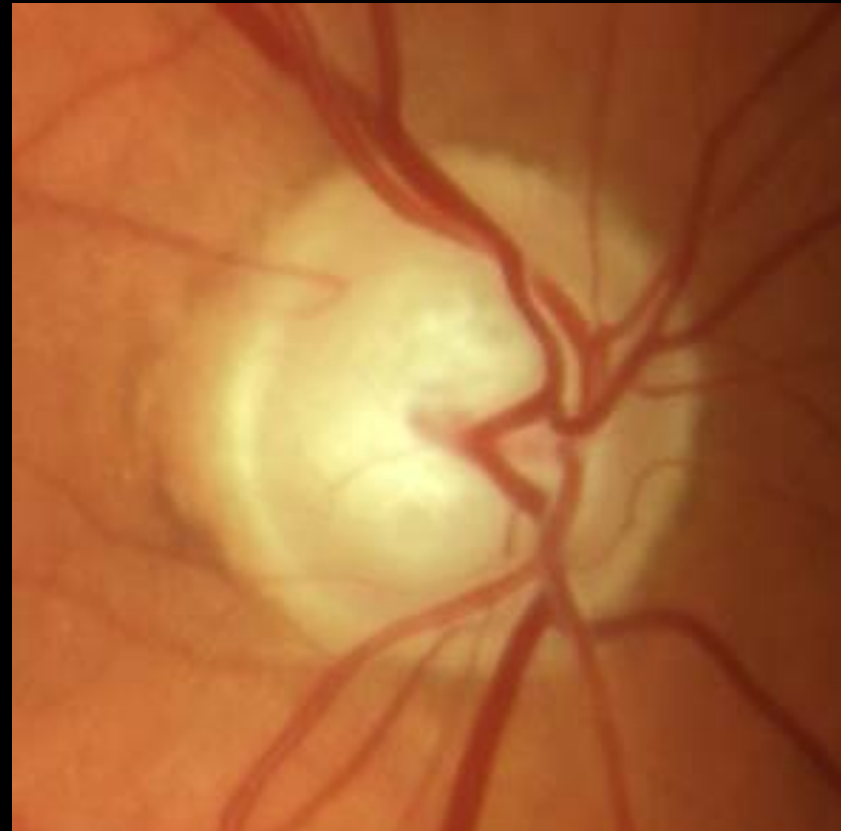

# Male, age 63, glaucoma

EasyScan

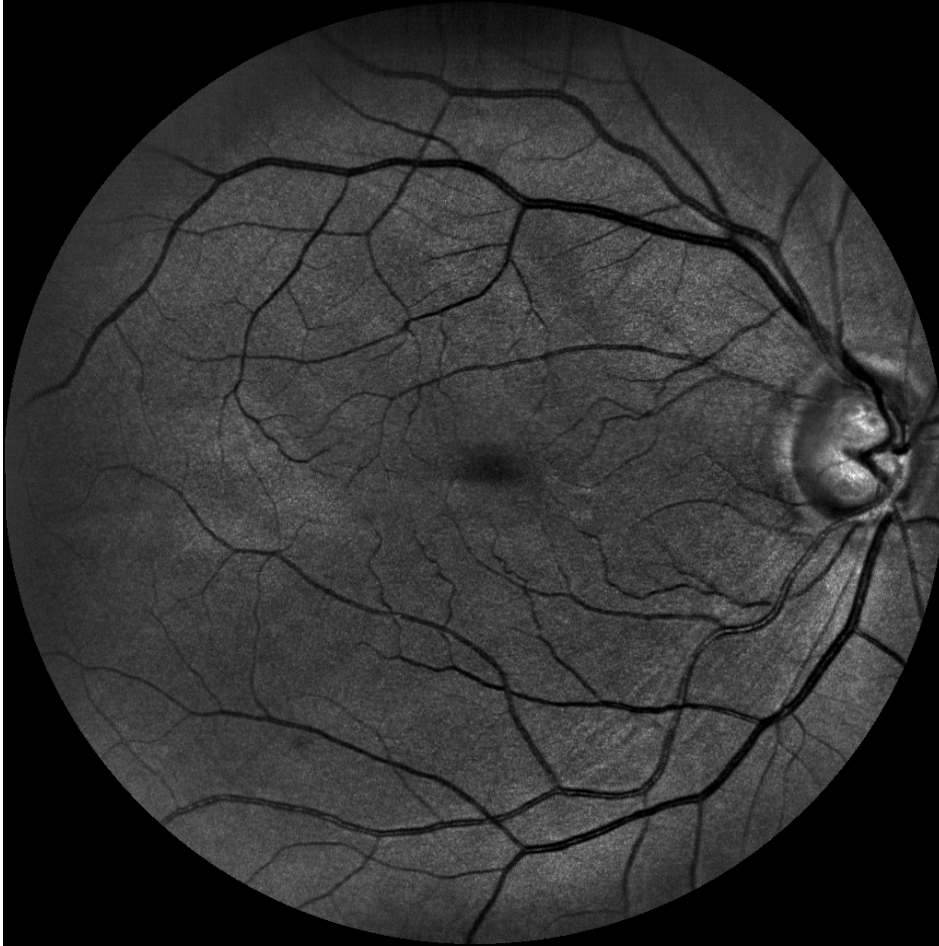

Canon

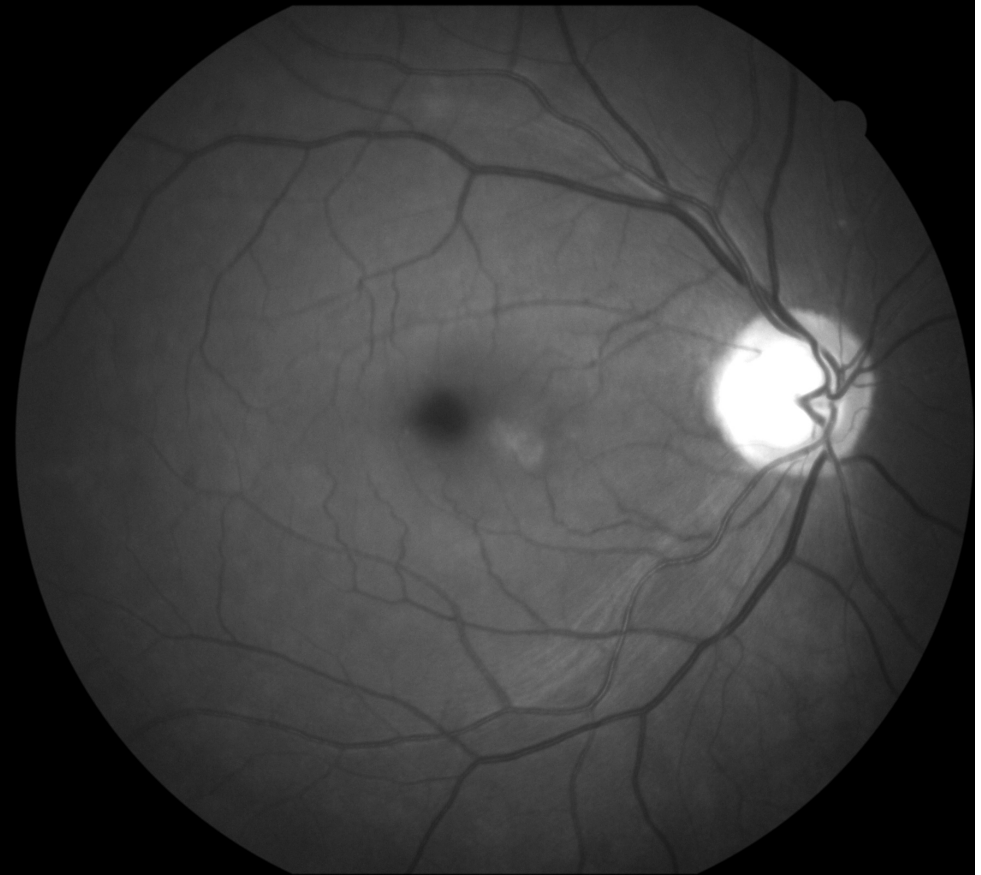


# Male, age 63, glaucoma

EasyScan green



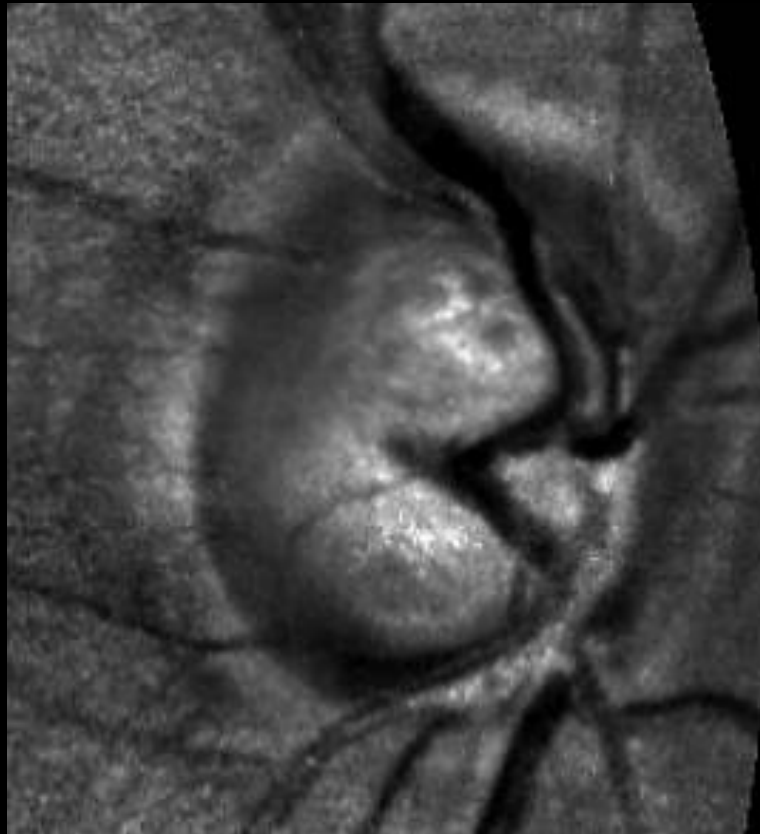
Canon cobalt



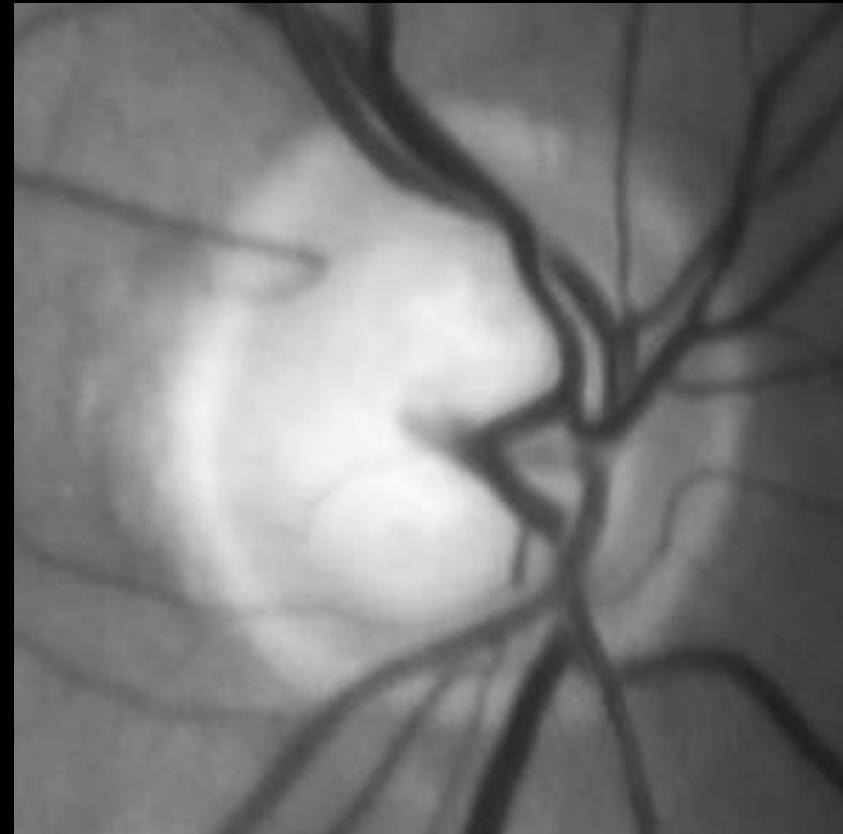


# Male, age 63, glaucoma

EasyScan green

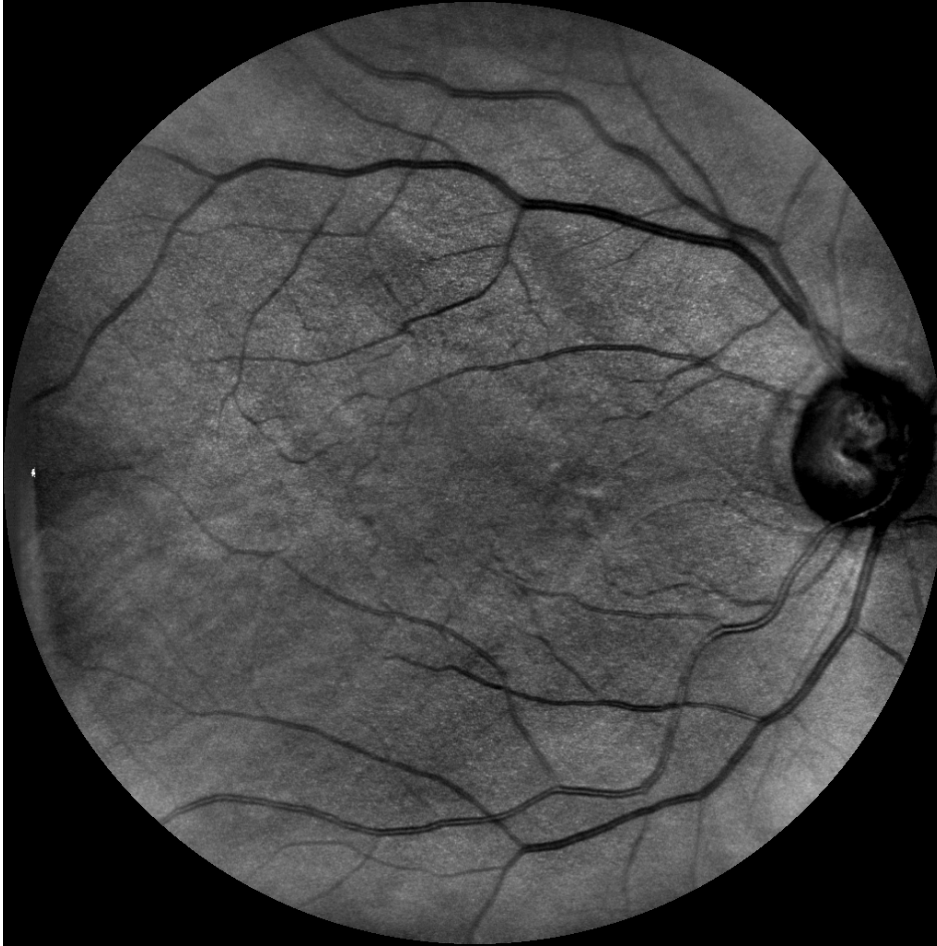

Canon cobalt

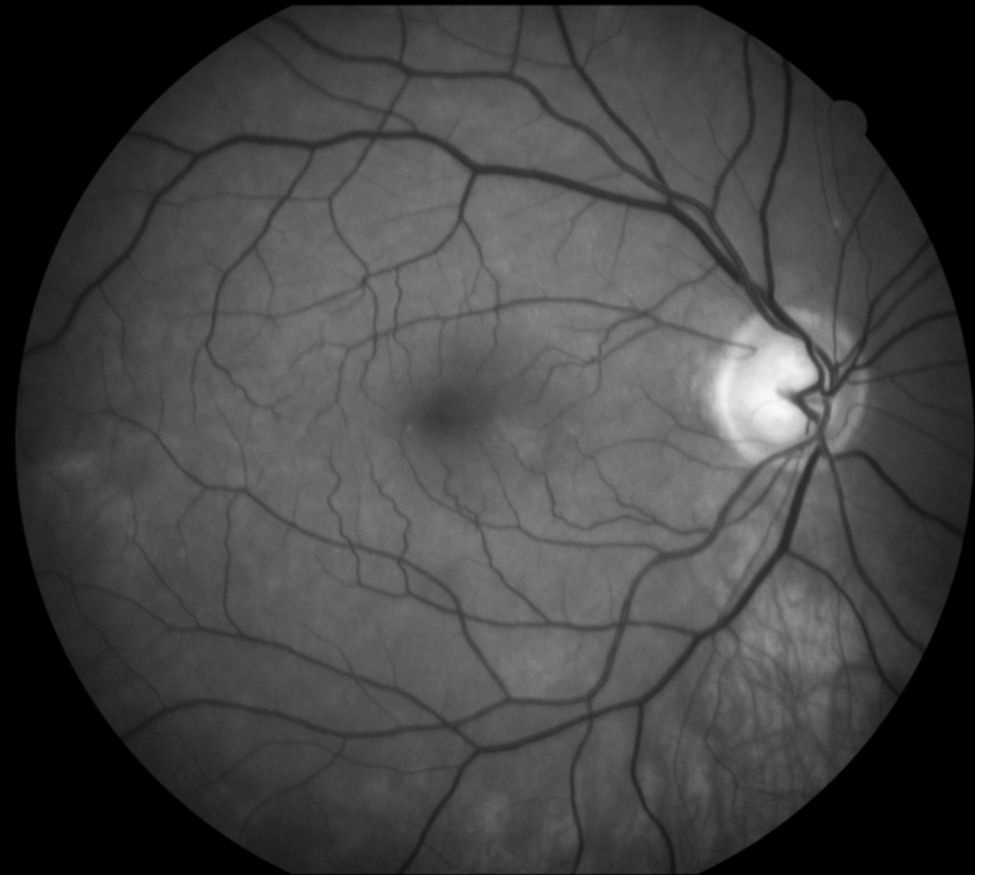

# Male, age 63, glaucoma

EasyScan near infrared

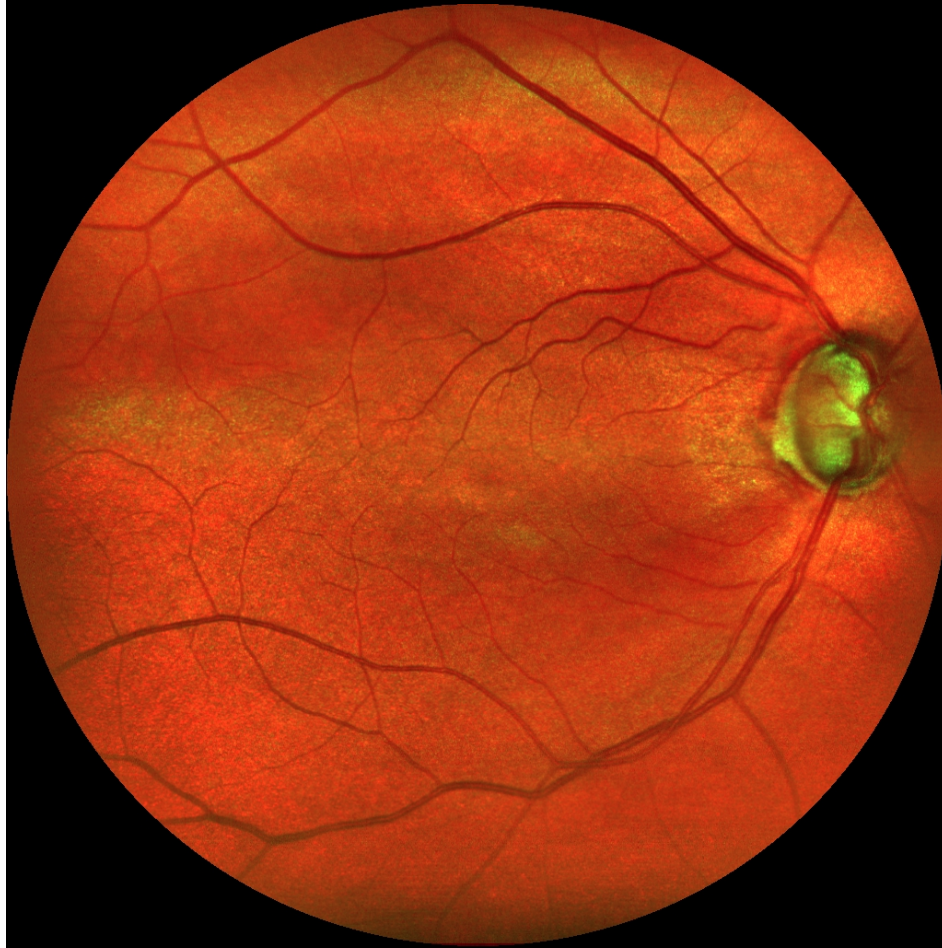

Canon green

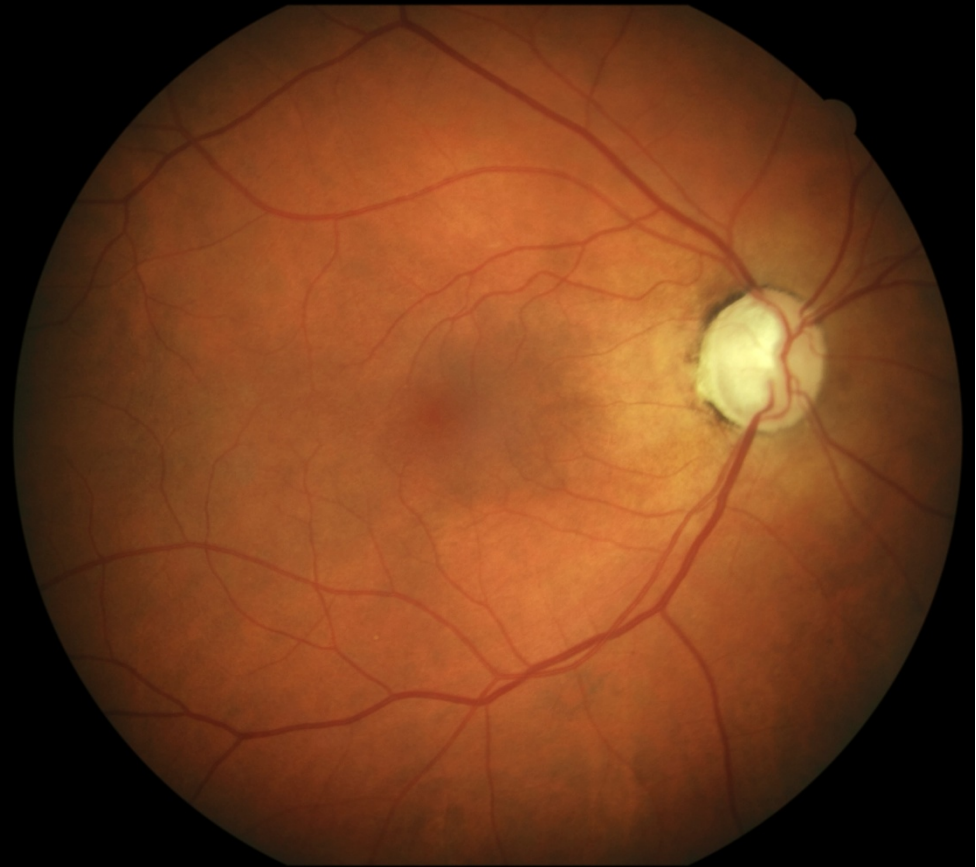

# Female, age 60, glaucoma

EasyScan



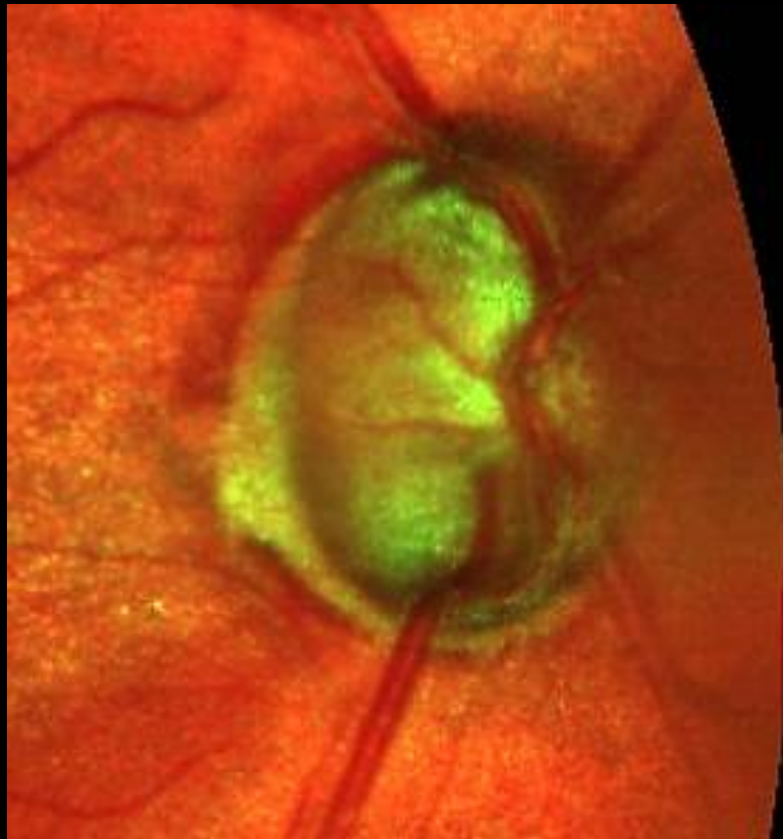Canon



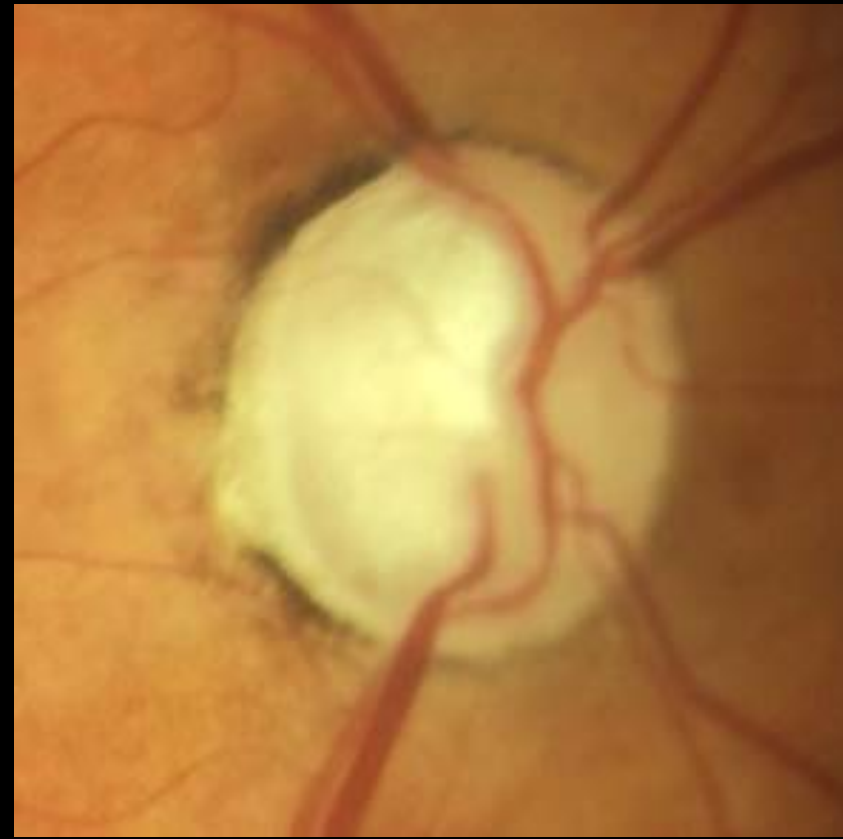

# Female, age 60, glaucoma

EasyScan

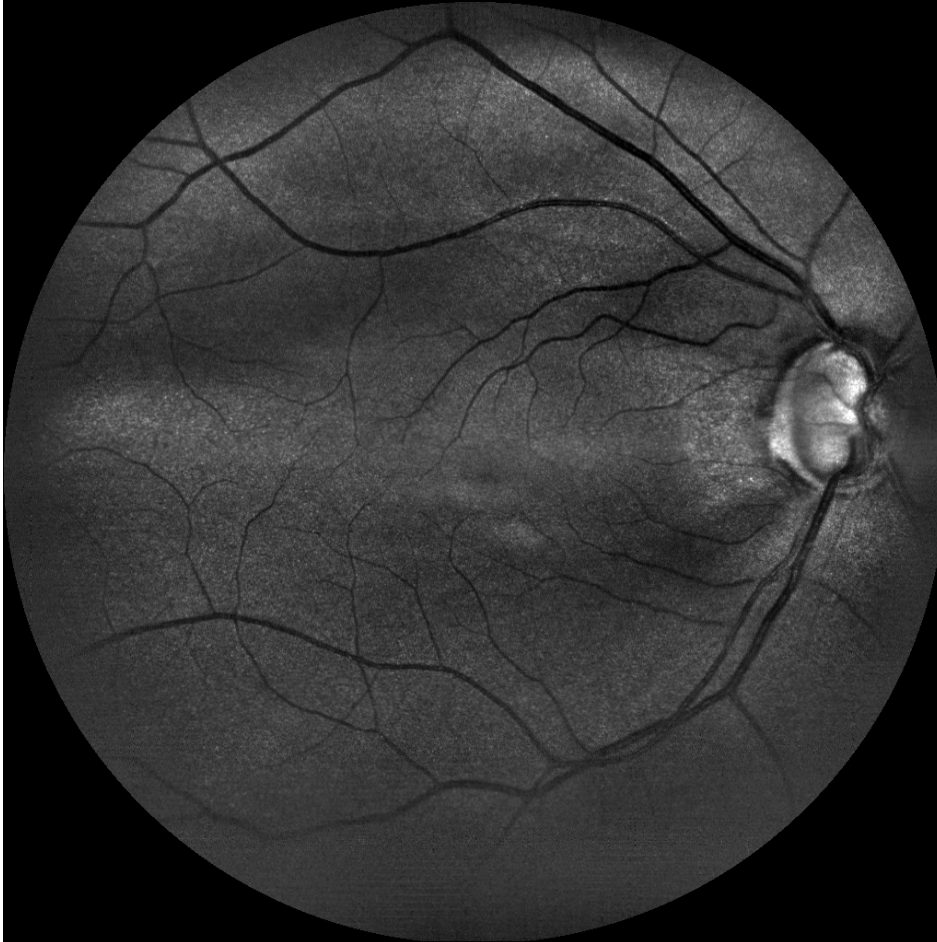

Canon

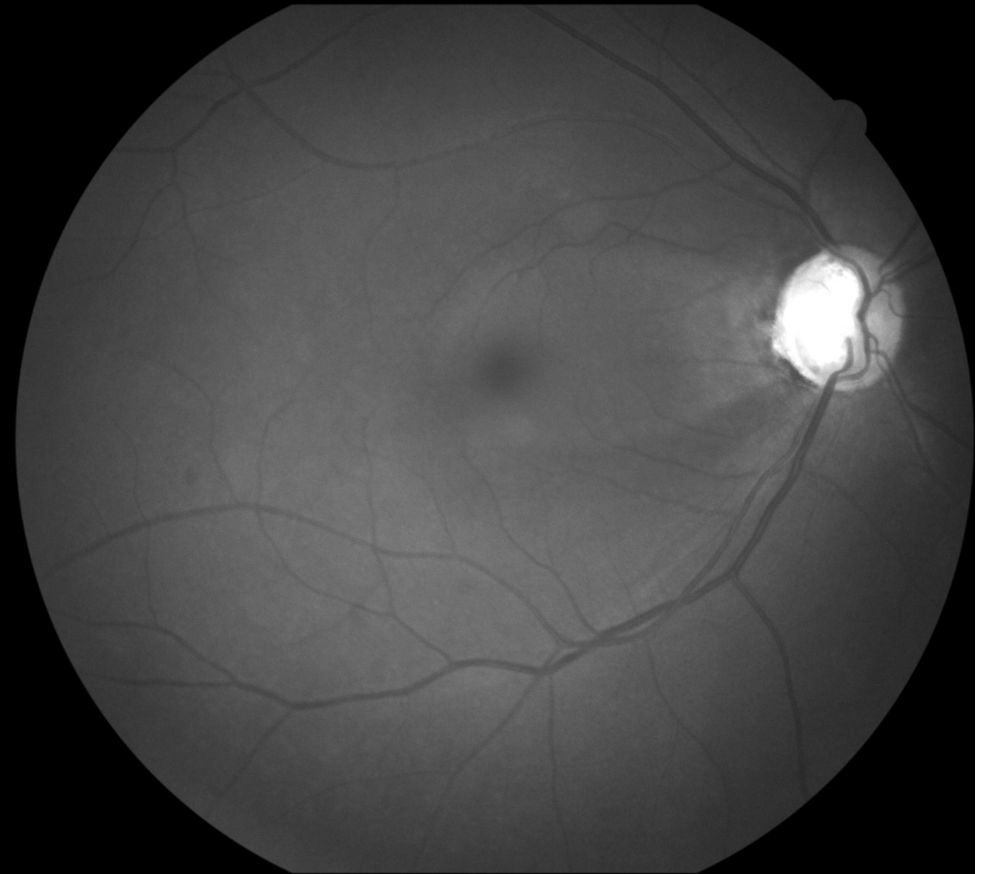


# Female, age 60, glaucoma

EasyScan green



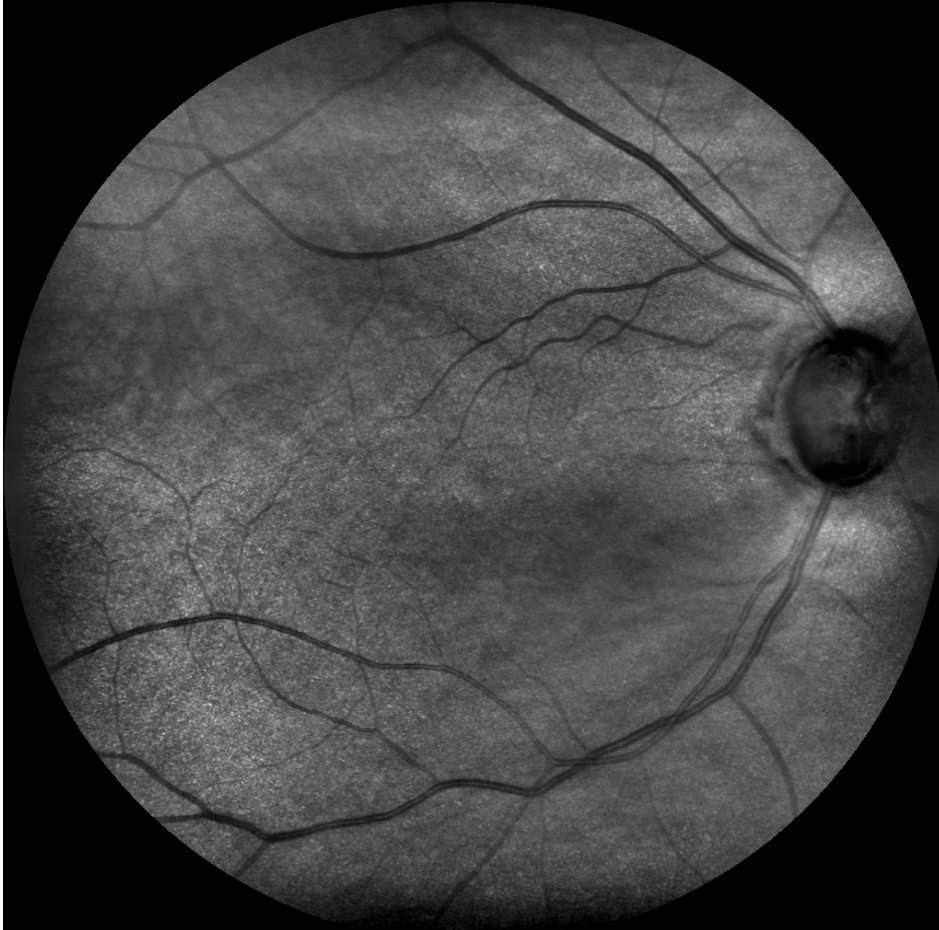Canon cobalt



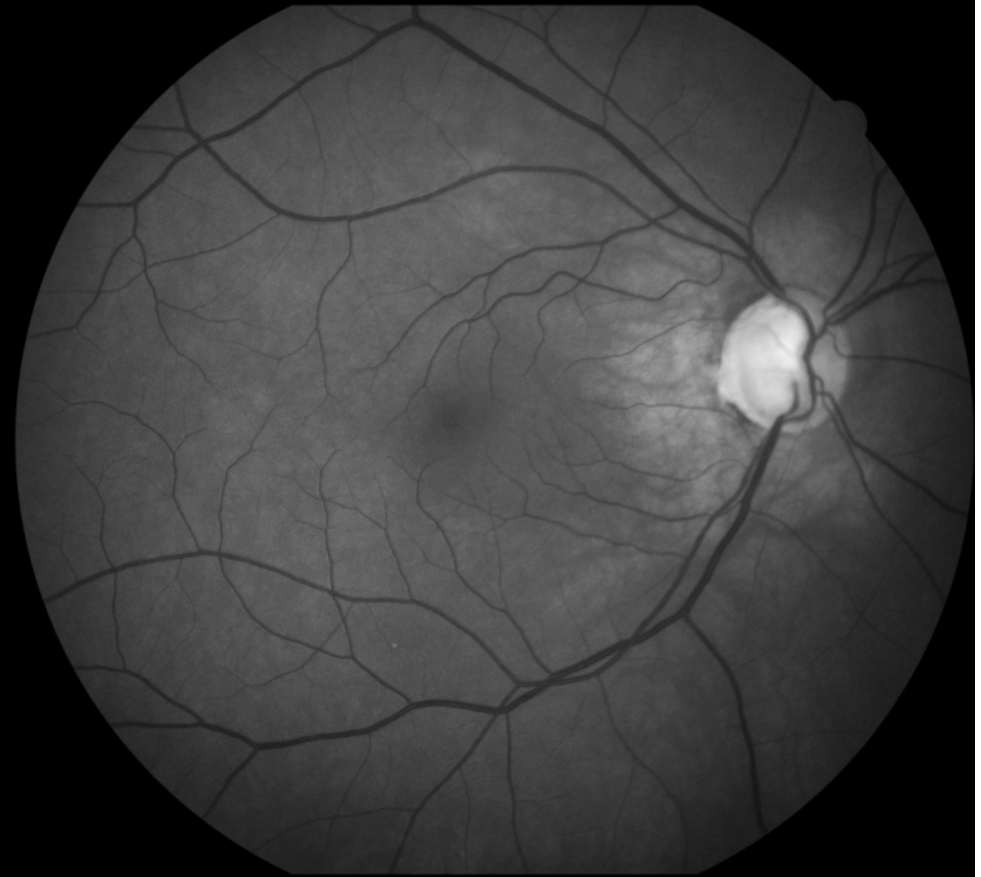

# Female, age 60, glaucoma

EasyScan near infrared

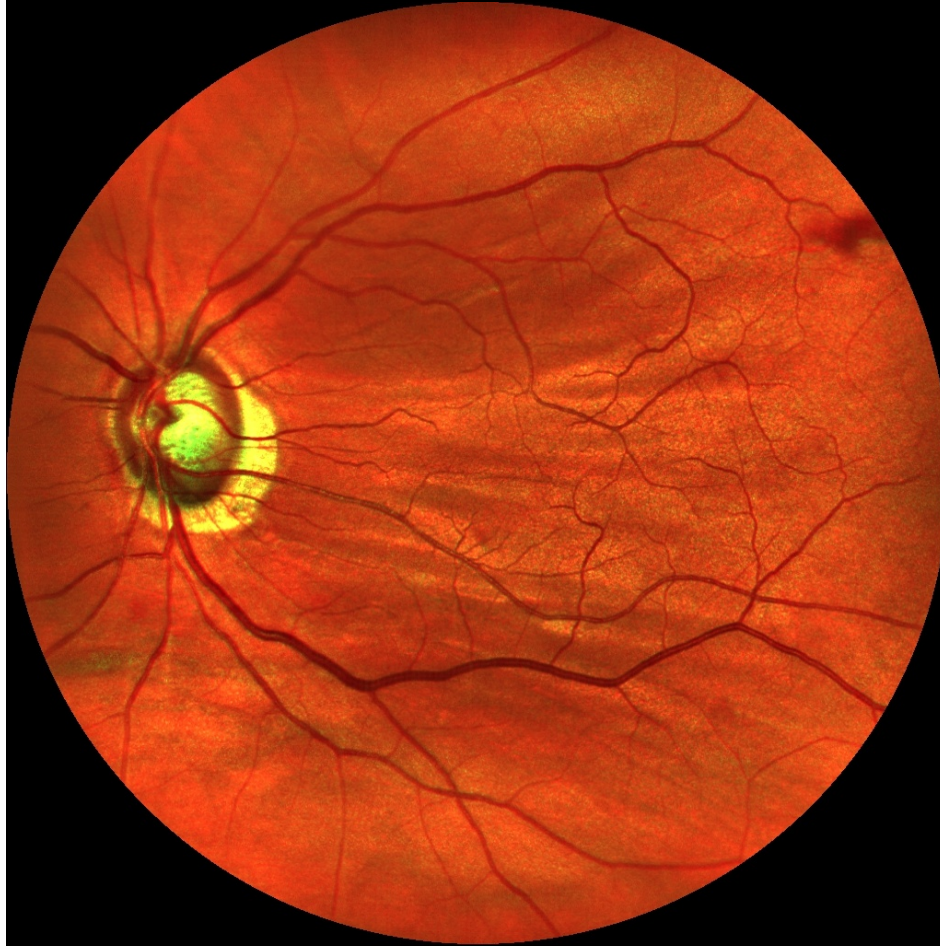

Canon green

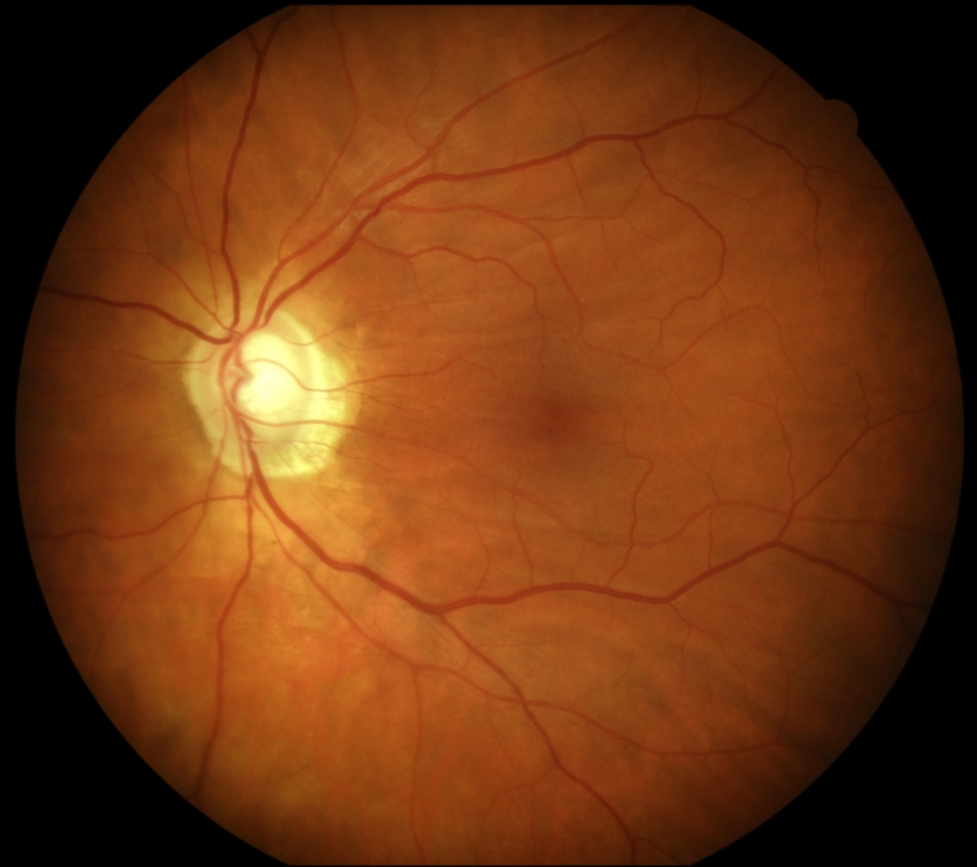

# Male, age 58, glaucoma, cataract

EasyScan



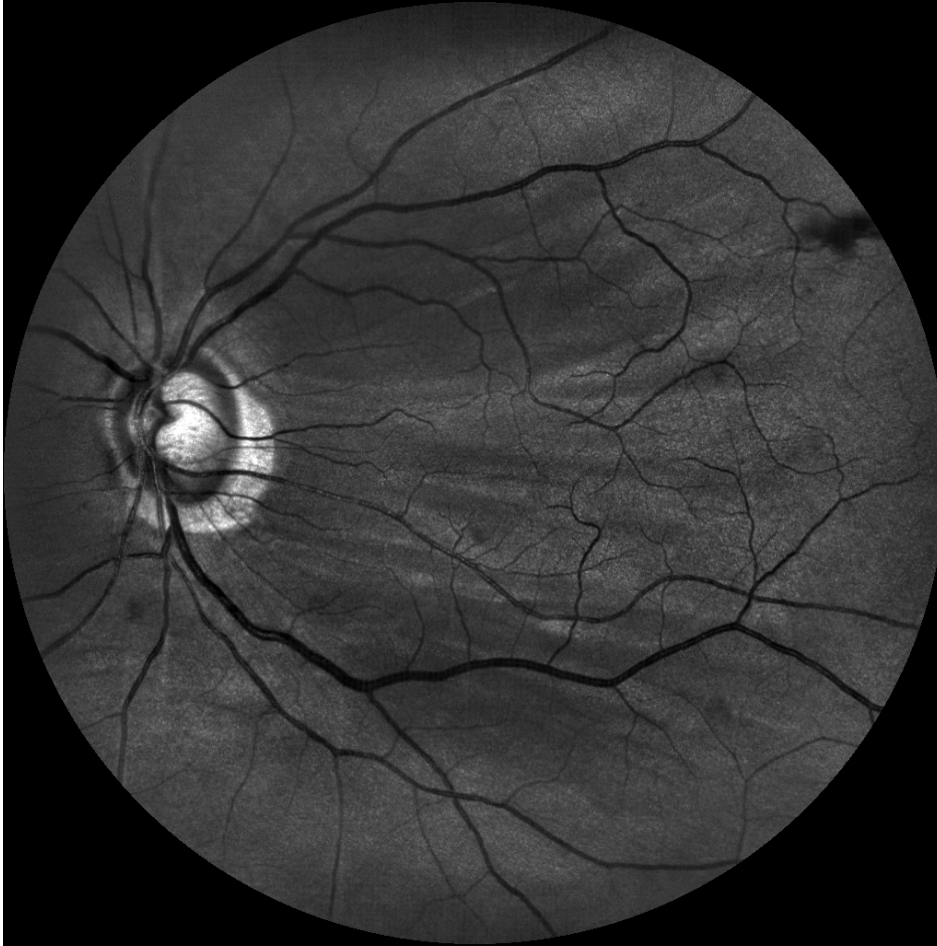Canon



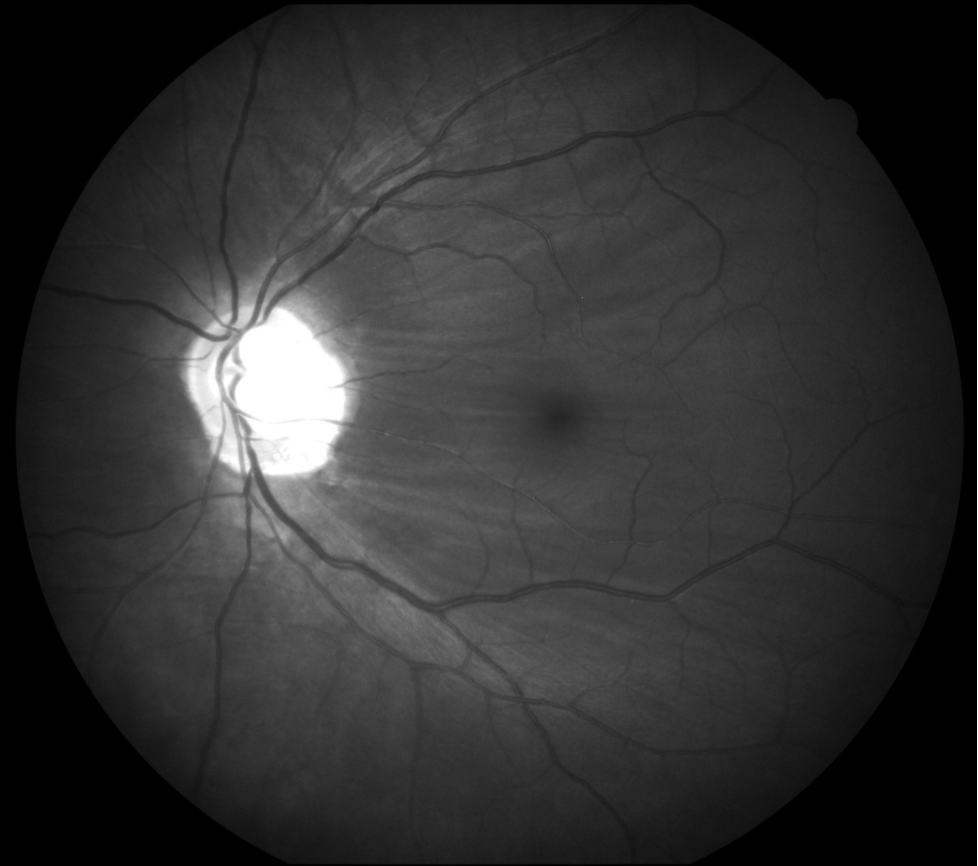


# Male, age 58, glaucoma, cataract

EasyScan green

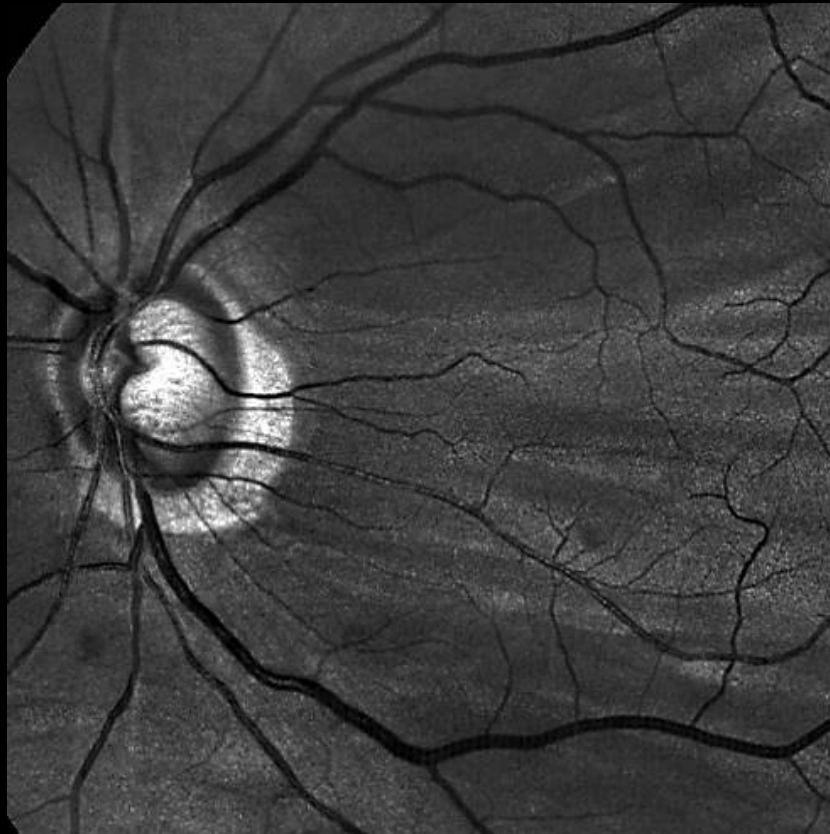


Canon cobalt

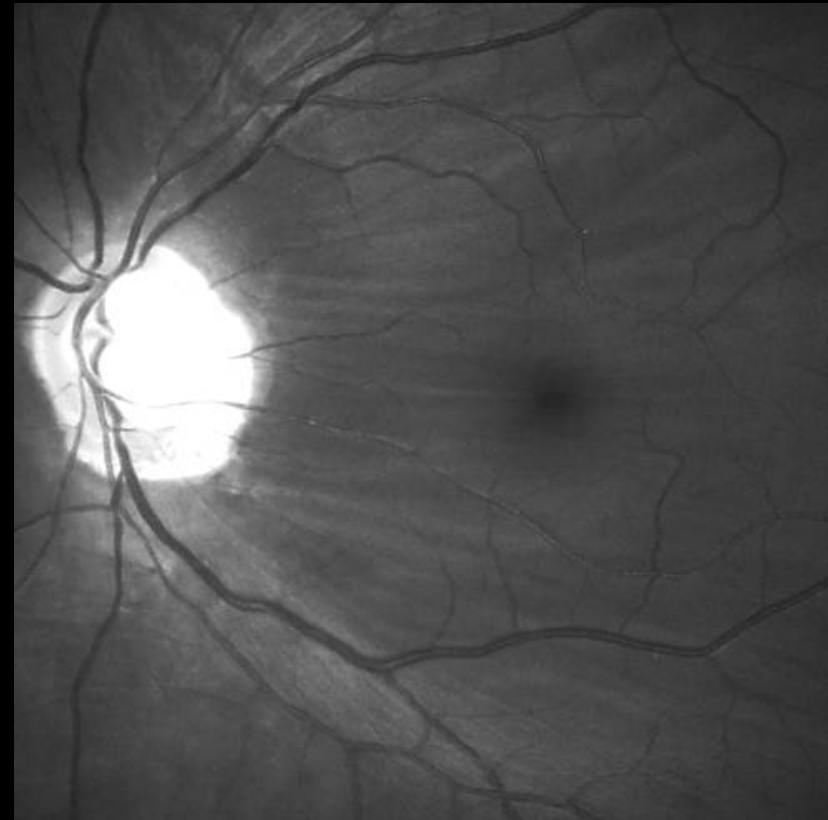


# Male, age 58, glaucoma, cataract

EasyScan green

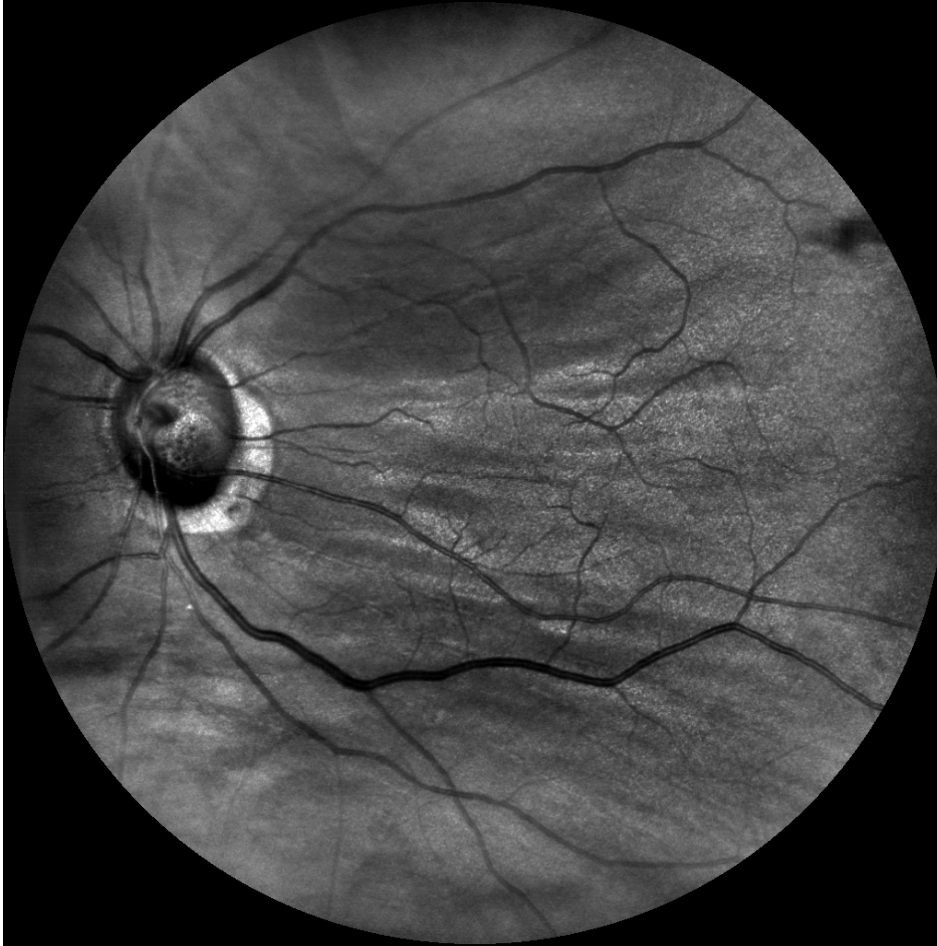

Canon cobalt

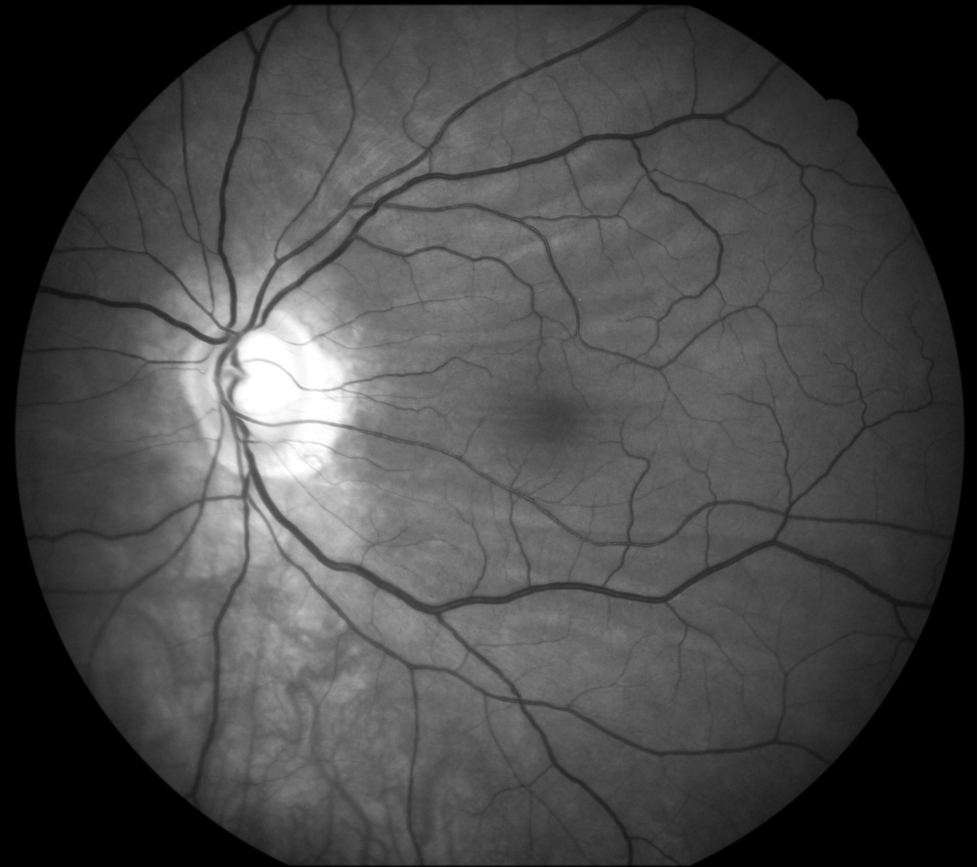

# Male, age 58, glaucoma, cataract

EasyScan near infrared



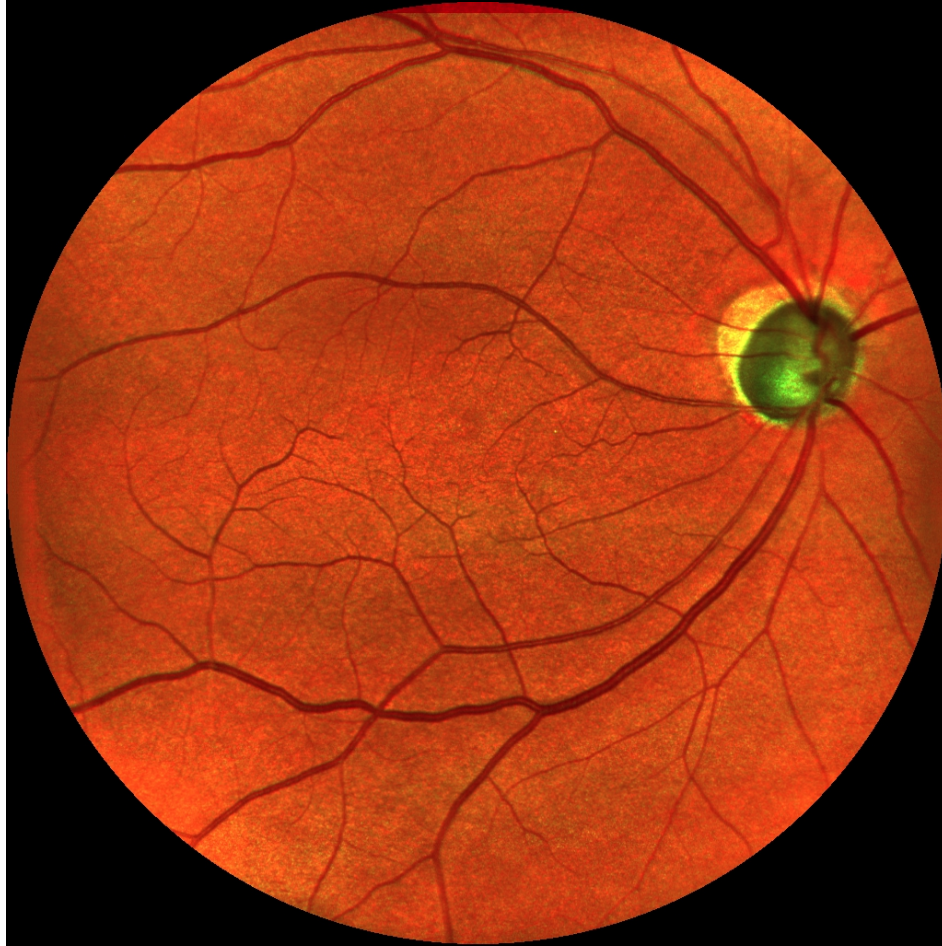Canon green



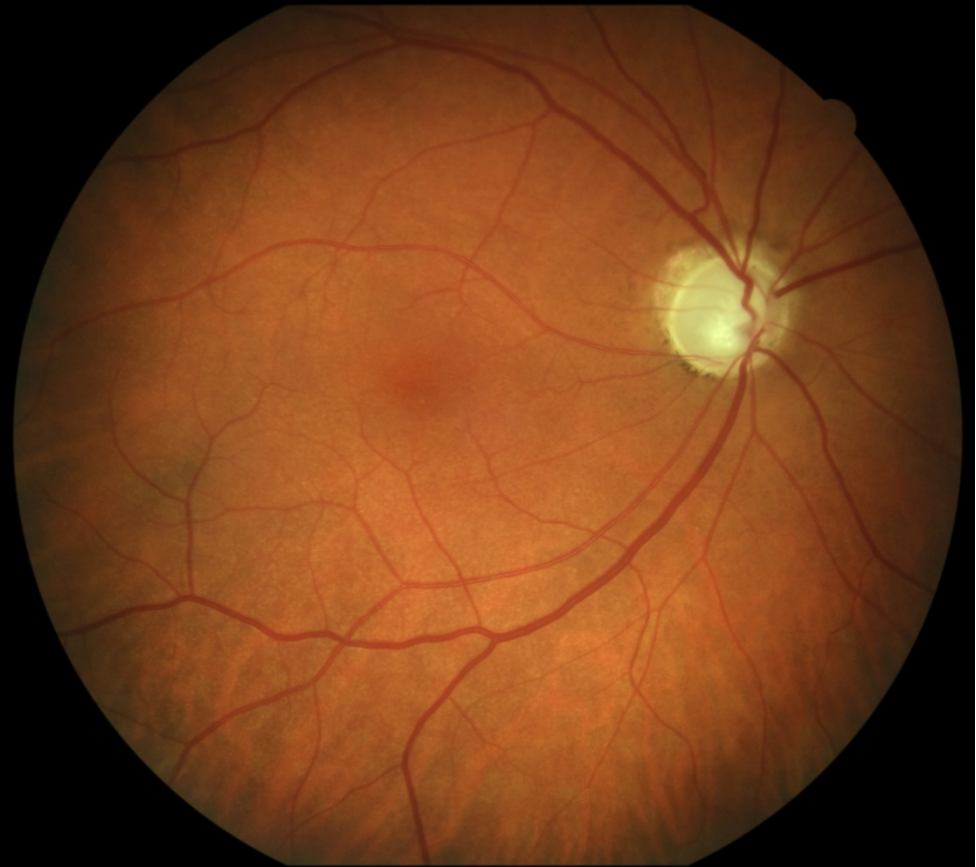

# Male, age 66, glaucoma

EasyScan

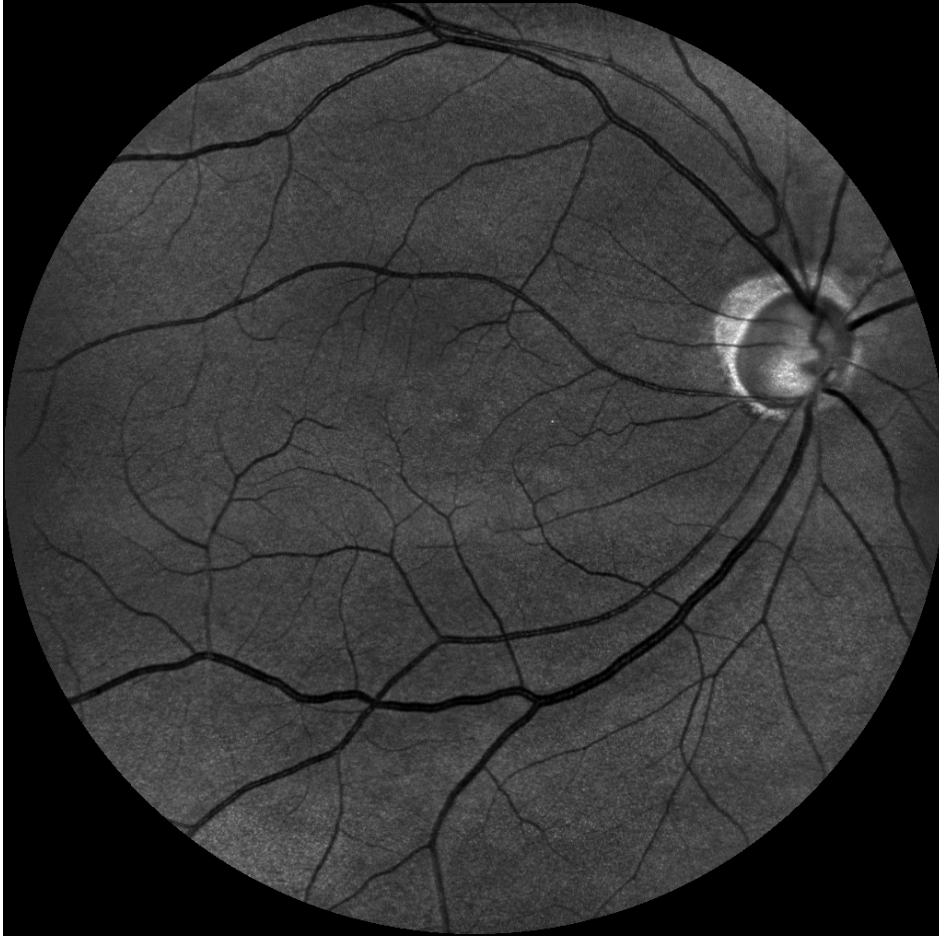


Canon

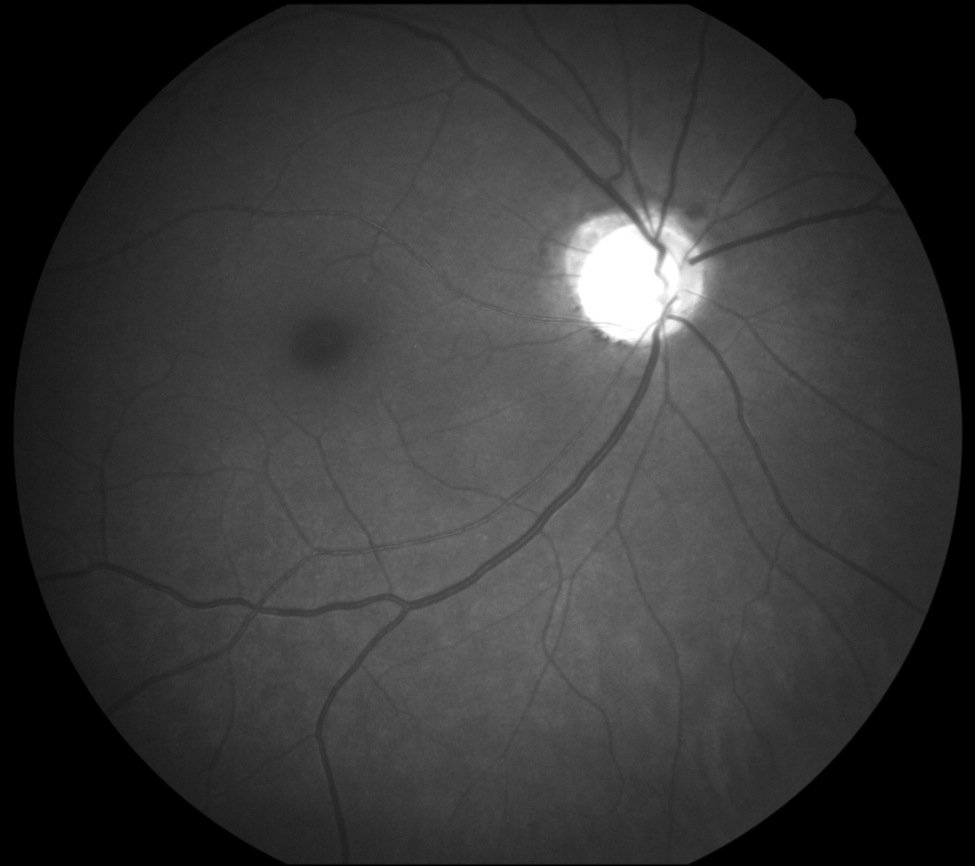


# Male, age 66, glaucoma

EasyScan green



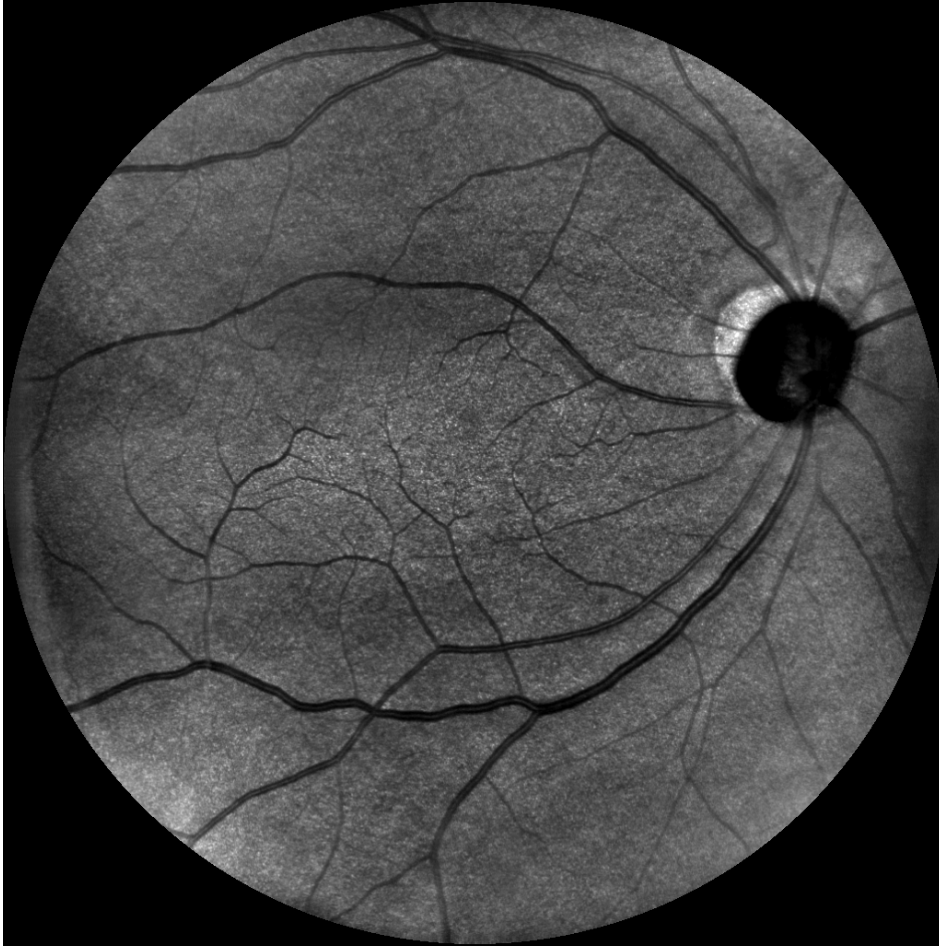Canon cobalt



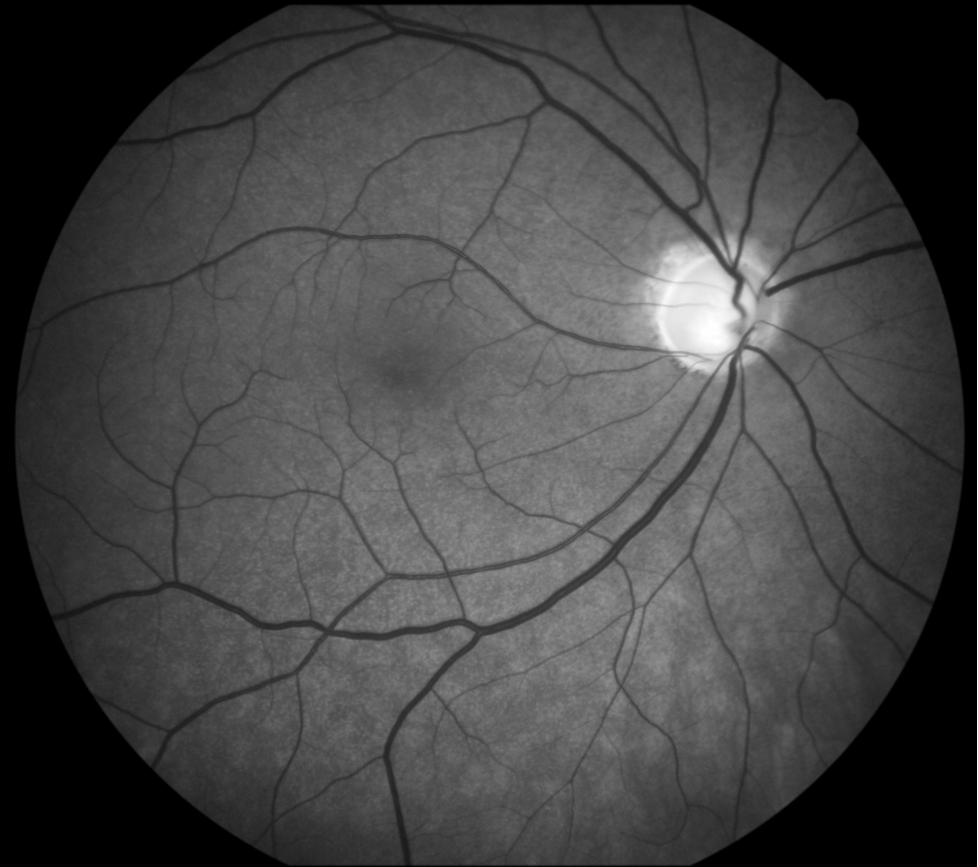

# Male, age 66, glaucoma

EasyScan near infrared



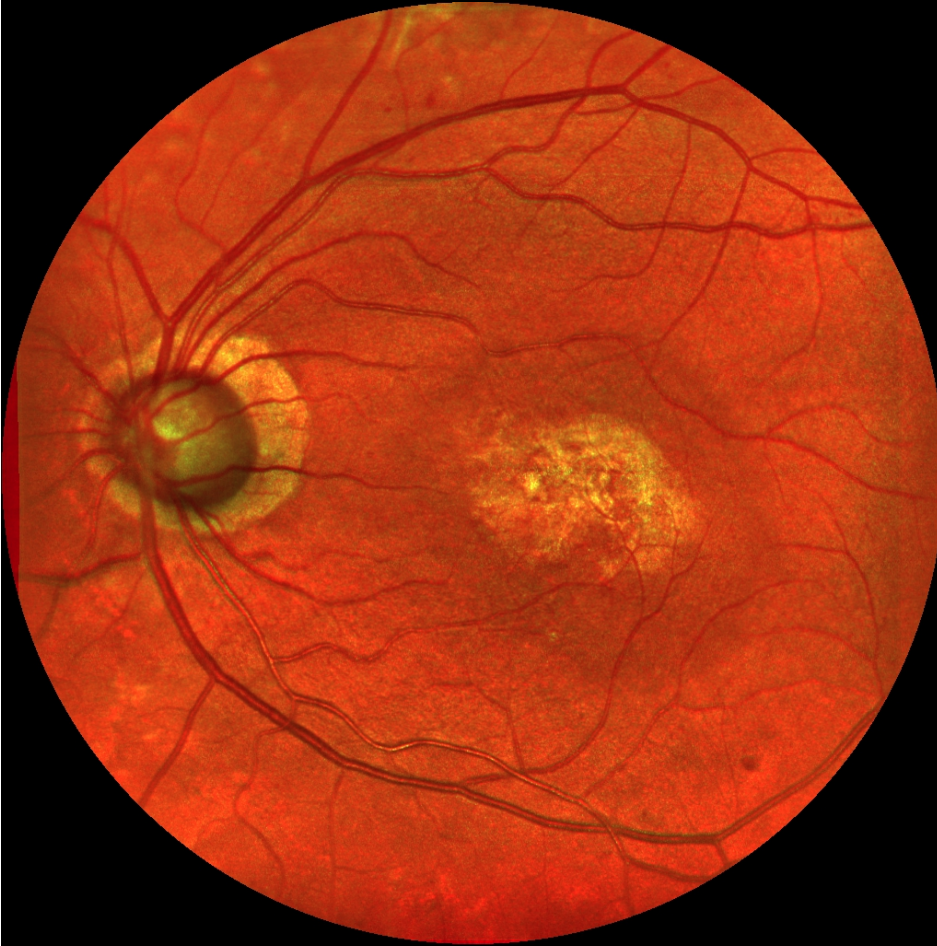
Canon green



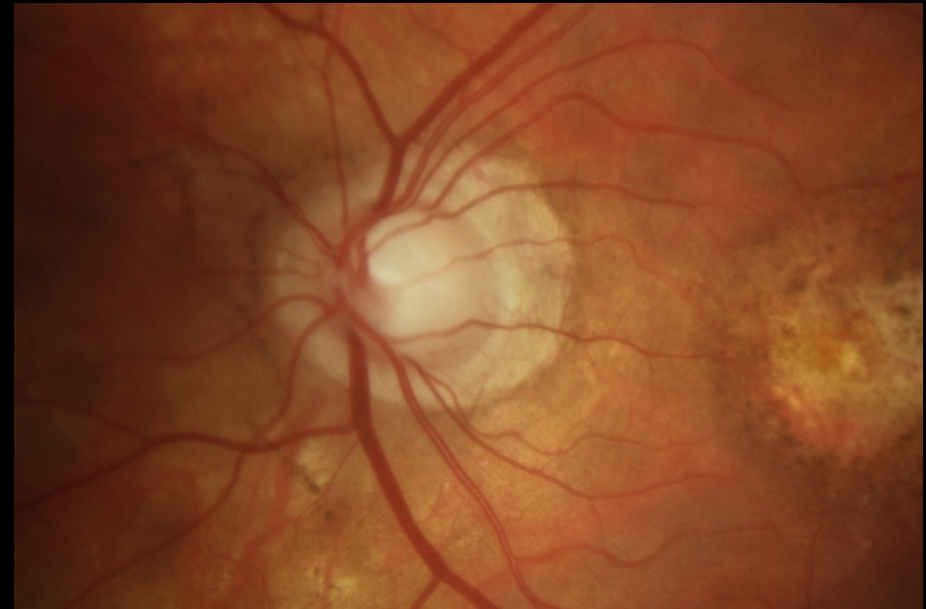


# Male, age 79, glaucoma, AMD, IOL

EasyScan

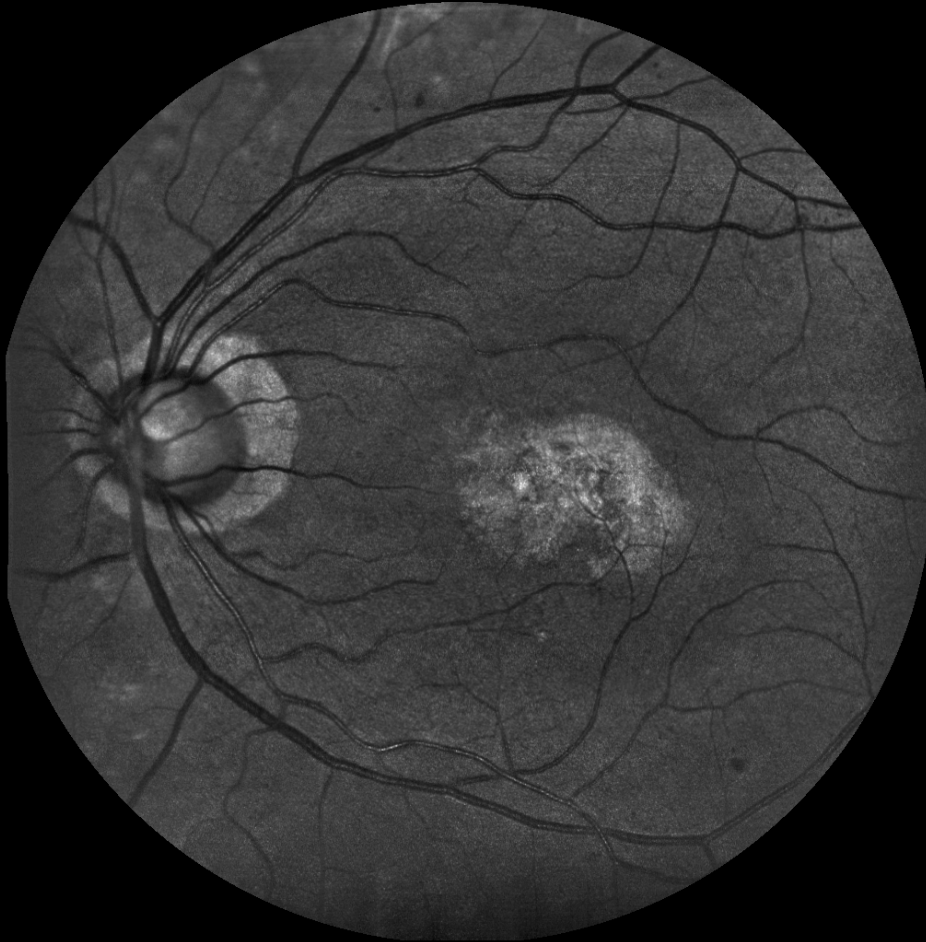

Canon, papilla

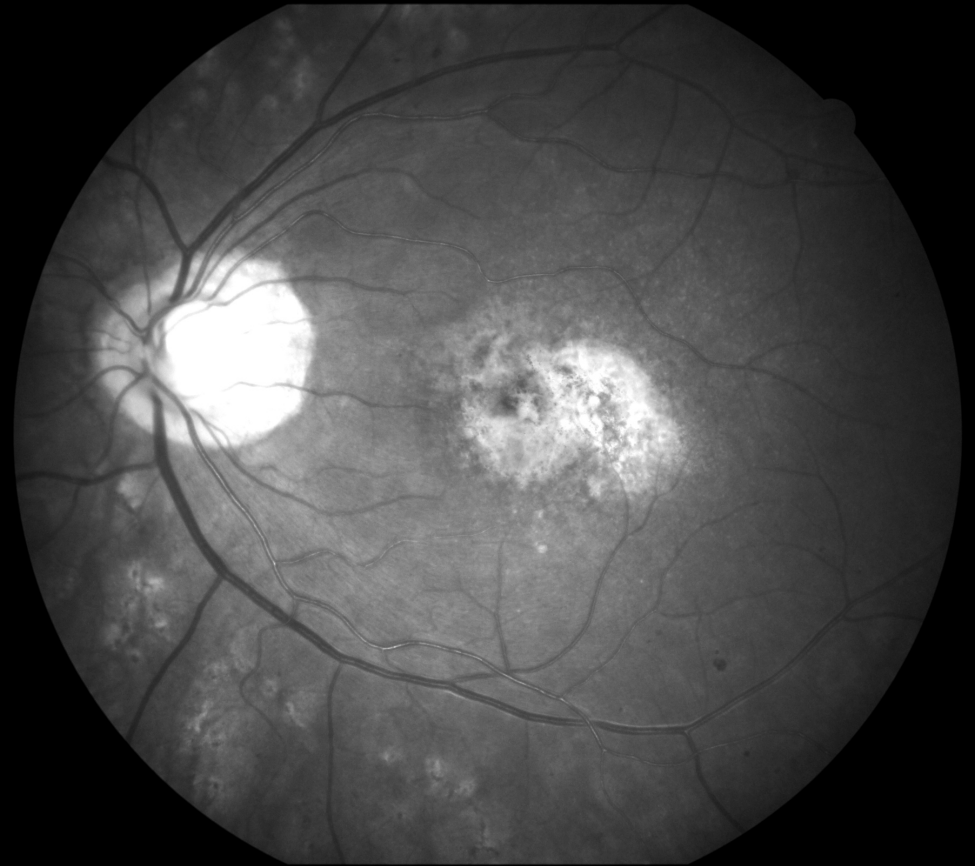


# Male, age 79, glaucoma, AMD, IOL

EasyScan green

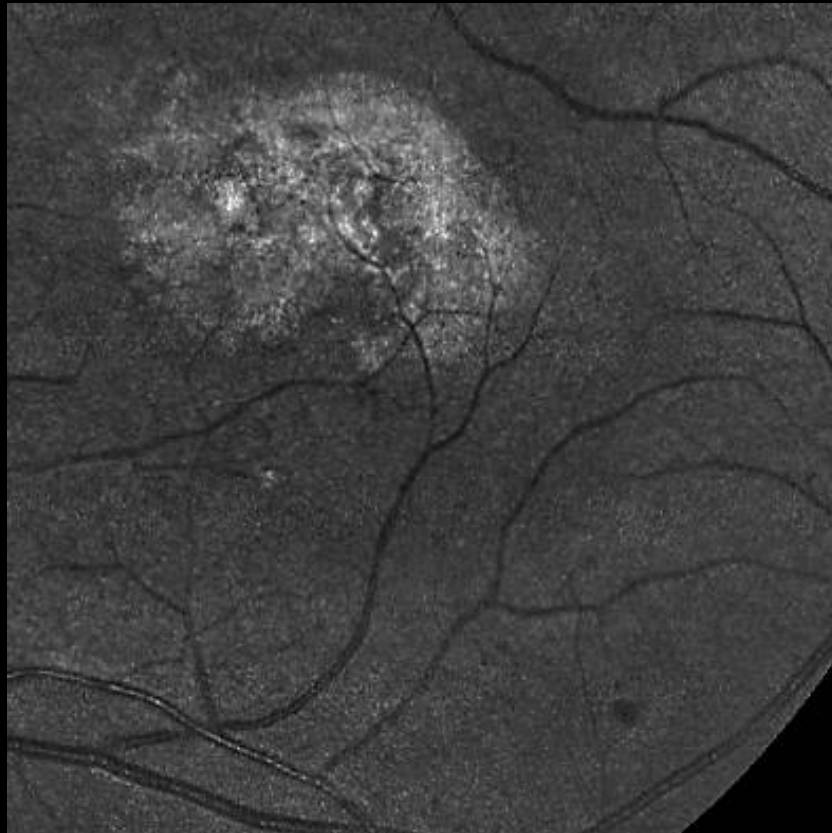


Canon cobalt

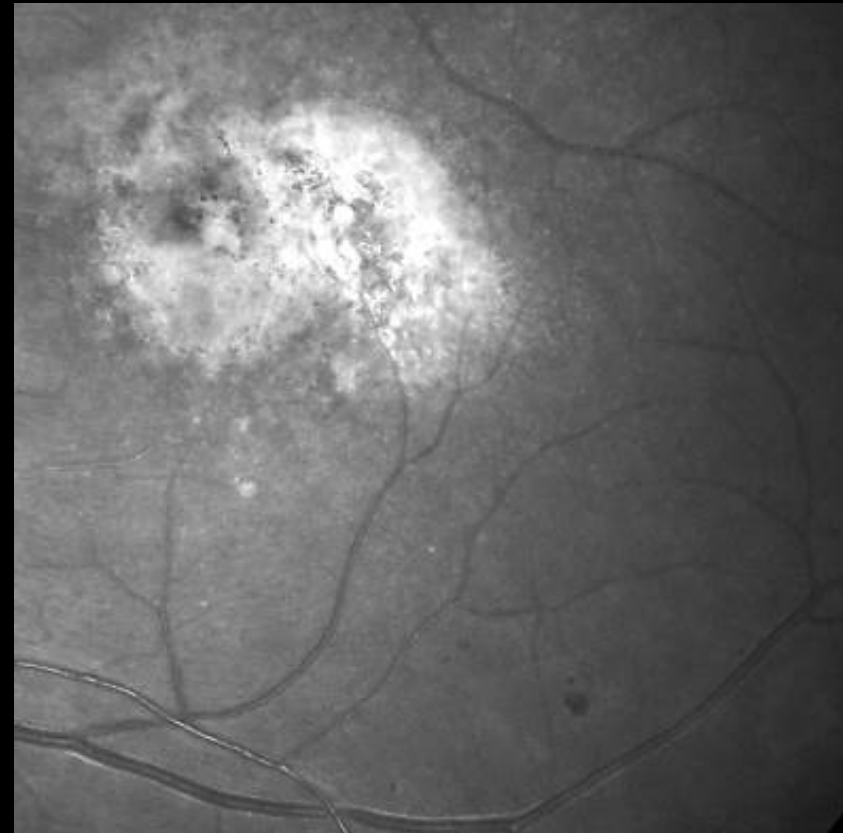


# Male, age 79, glaucoma, AMD, IOL

EasyScan green



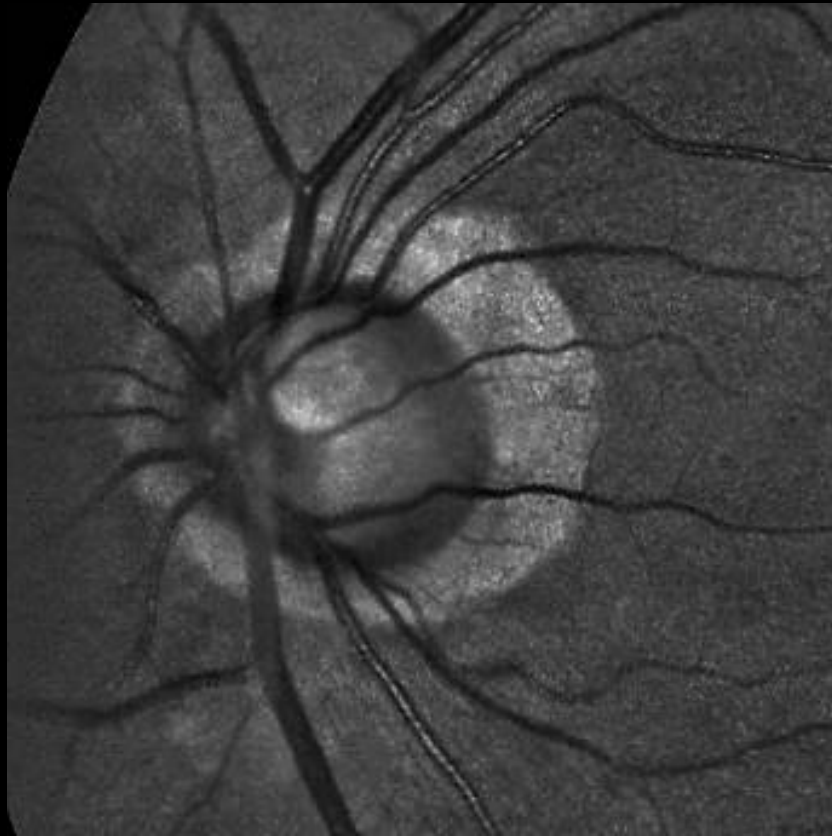
Canon cobalt



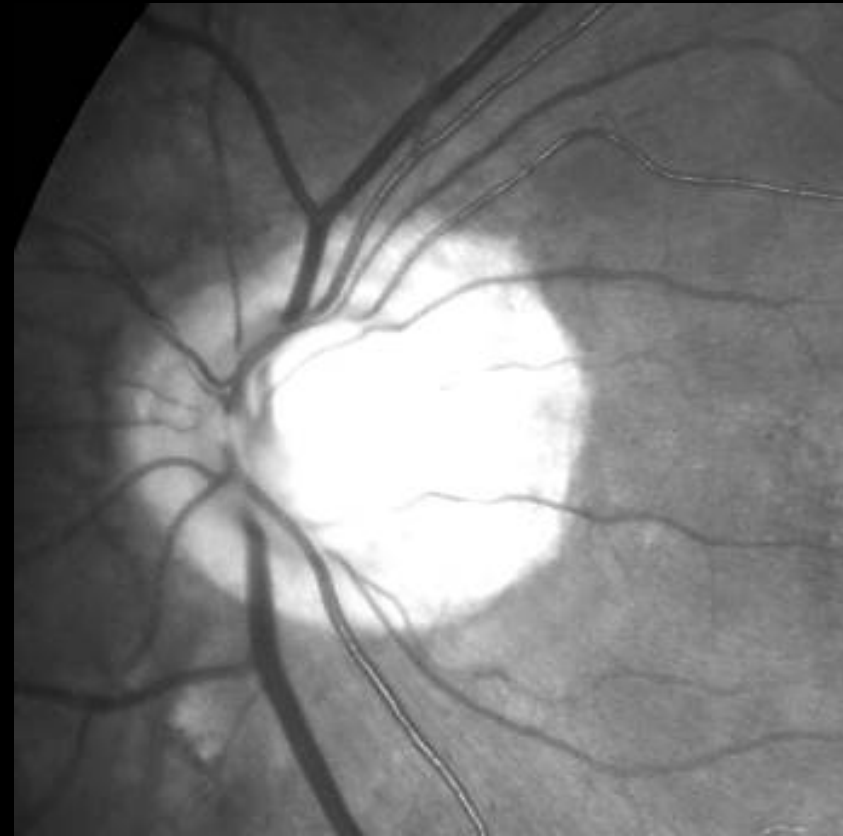


# Male, age 79, glaucoma, AMD, IOL

EasyScan green

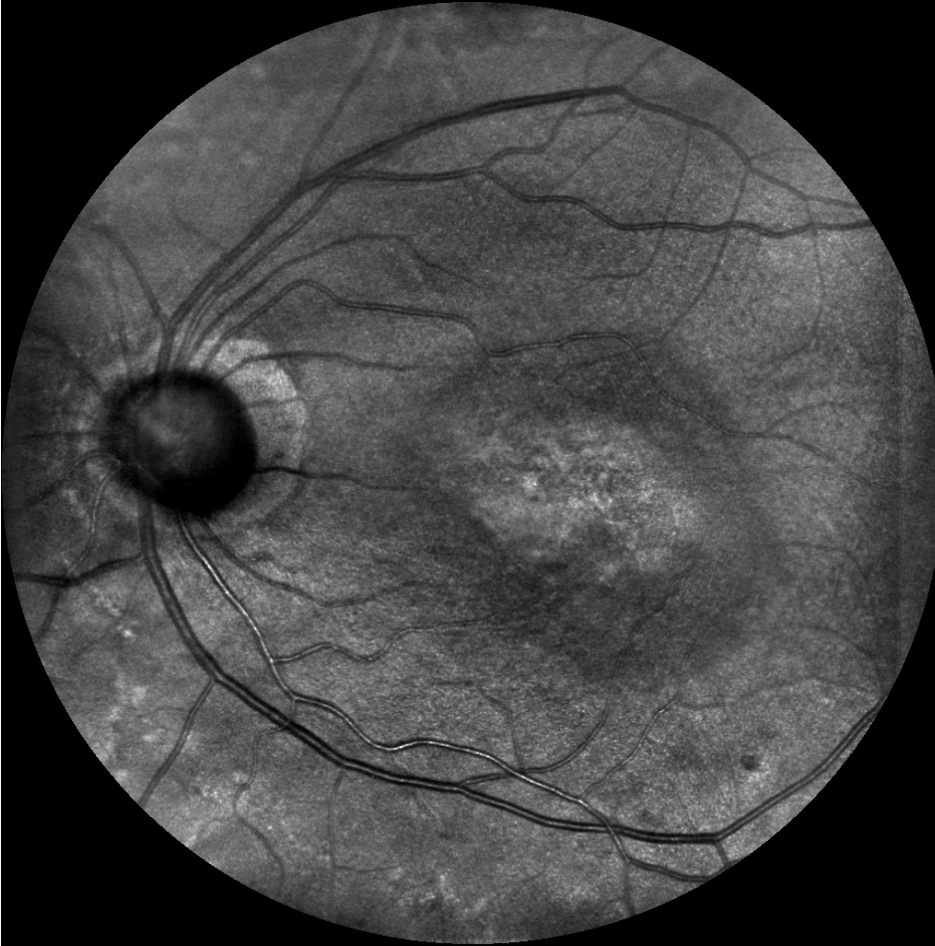

Canon cobalt

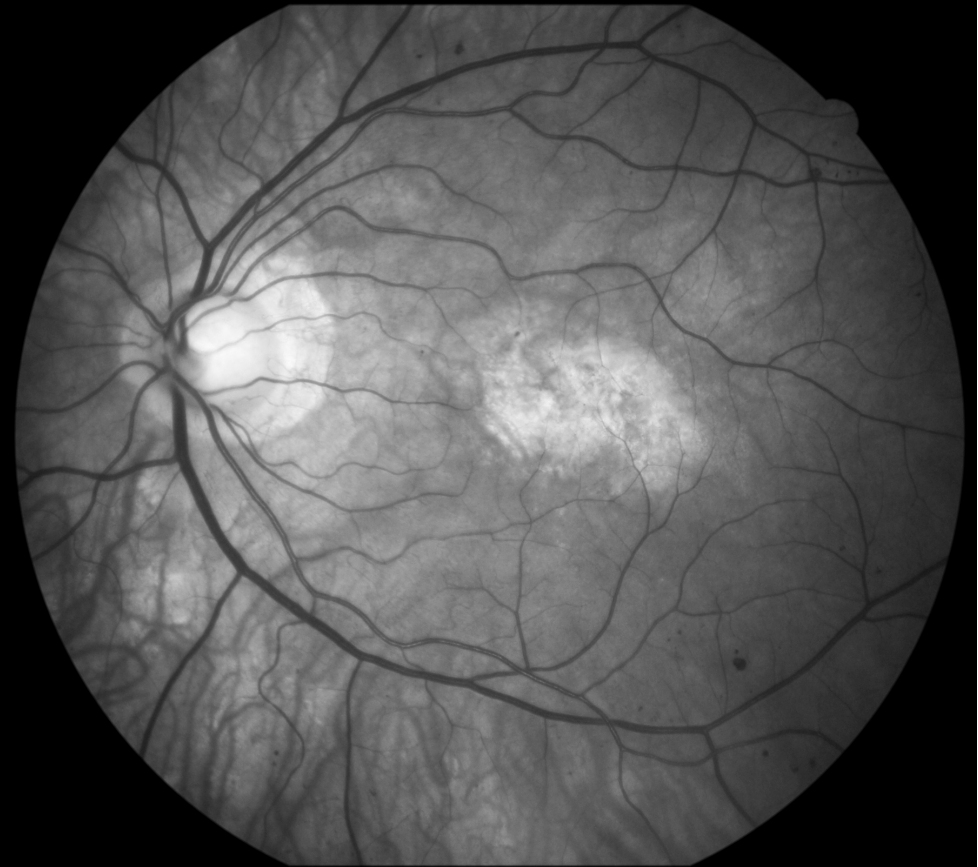


# Male, age 79, glaucoma, AMD, IOL

EasyScan near infrared

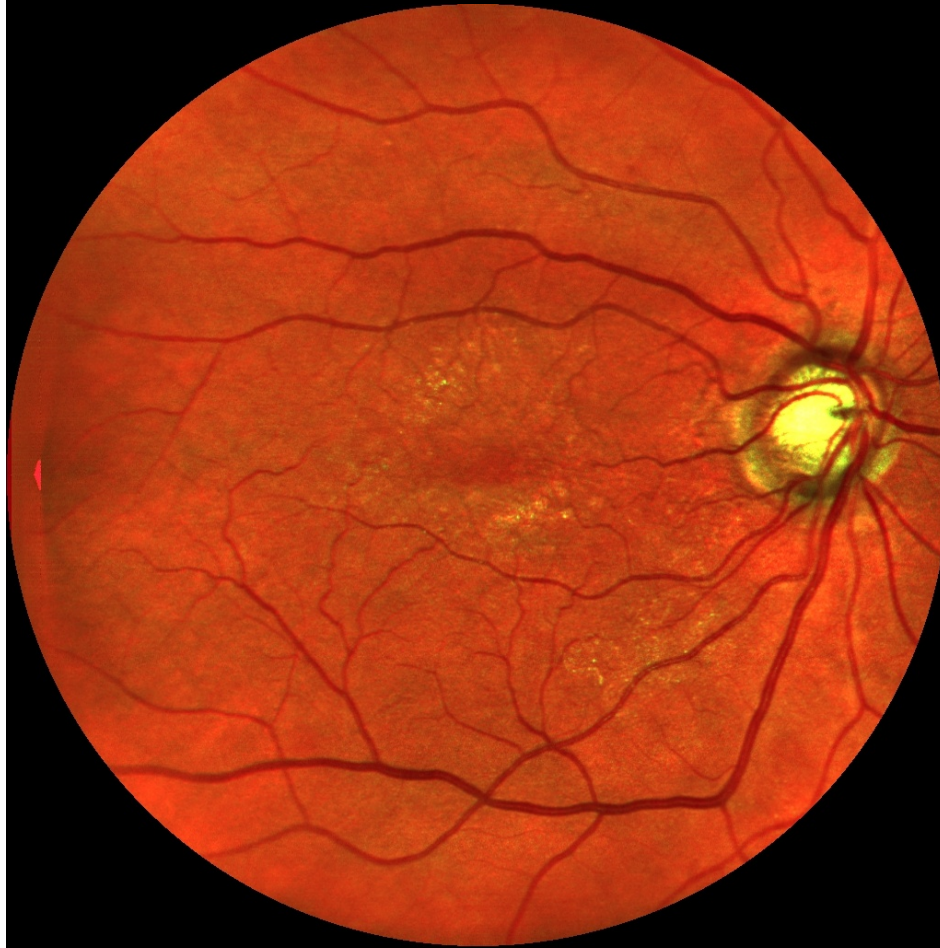

Canon green

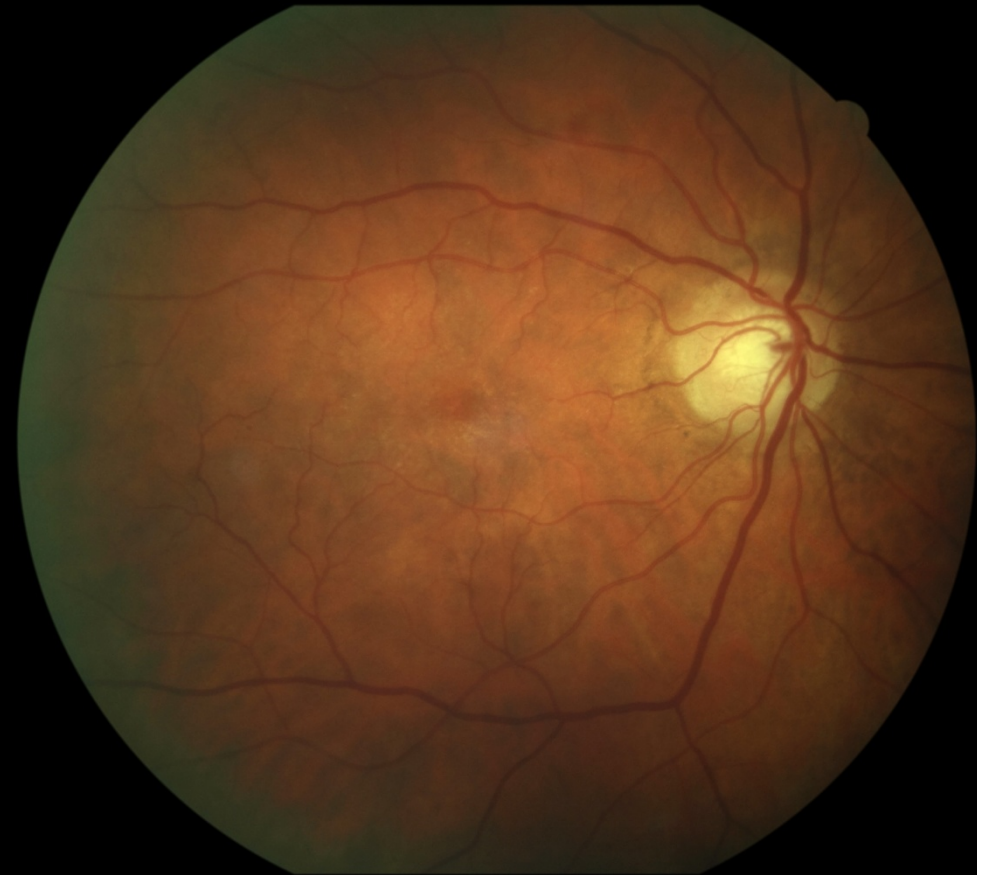


Female, age 69, glaucoma, diabetic maculopathy, cataract

EasyScan



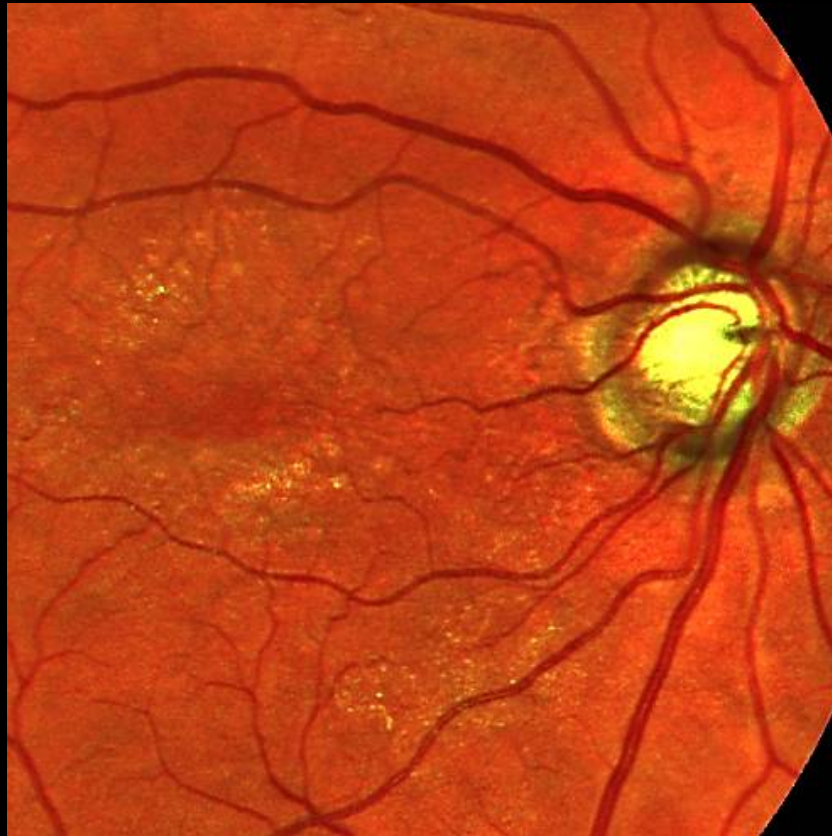Canon



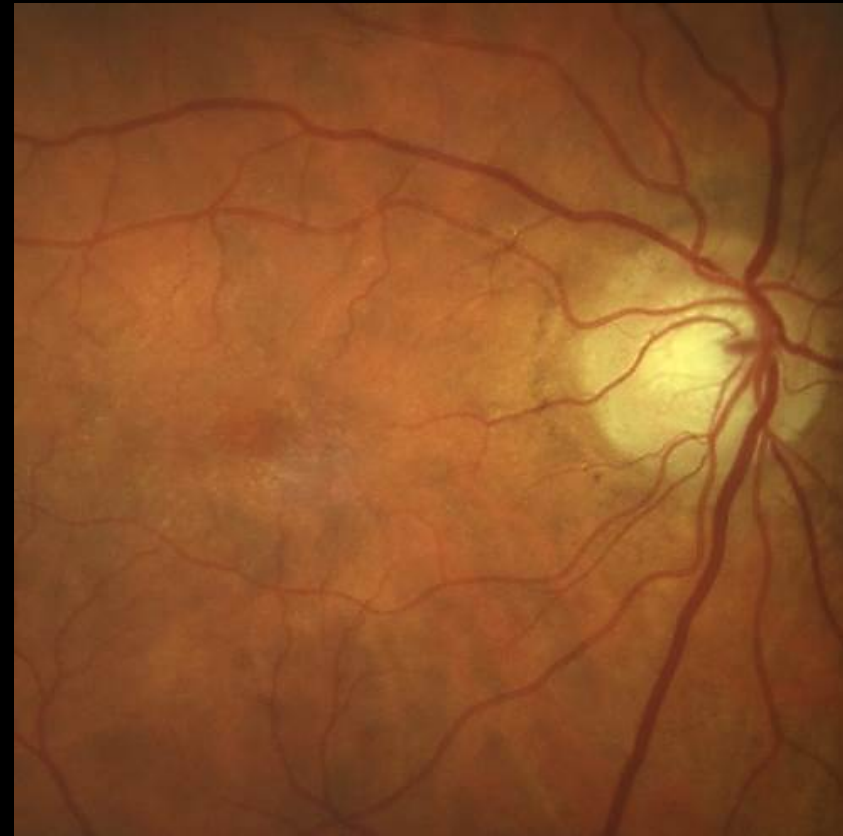

# Female, age 69, glaucoma, diabetic maculopathy, cataract

EasyScan

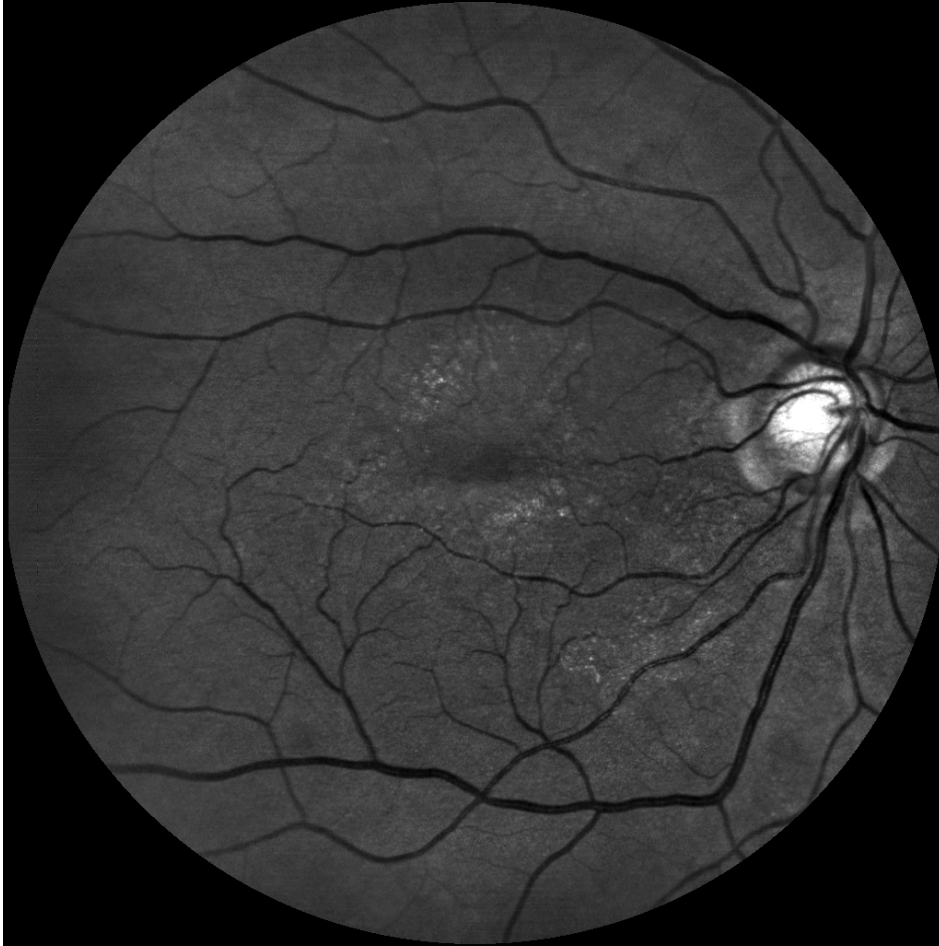

Canon

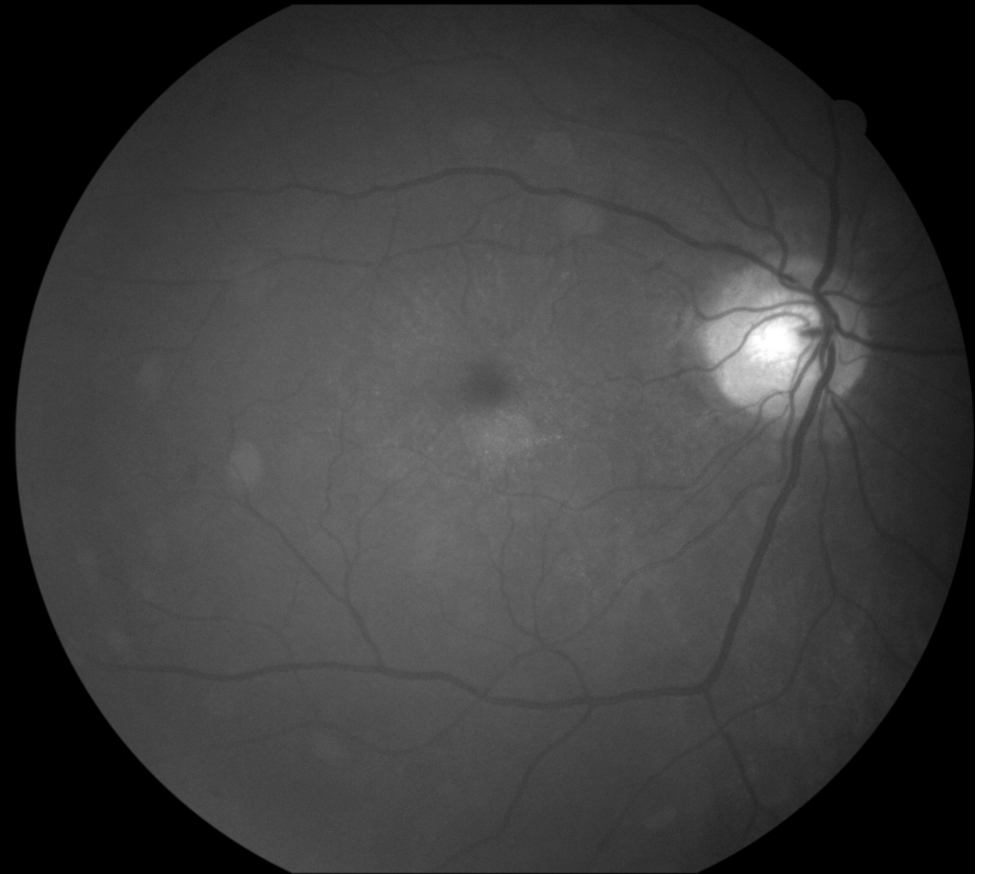


# Female, age 69, glaucoma, diabetic maculopathy, cataract

EasyScan green



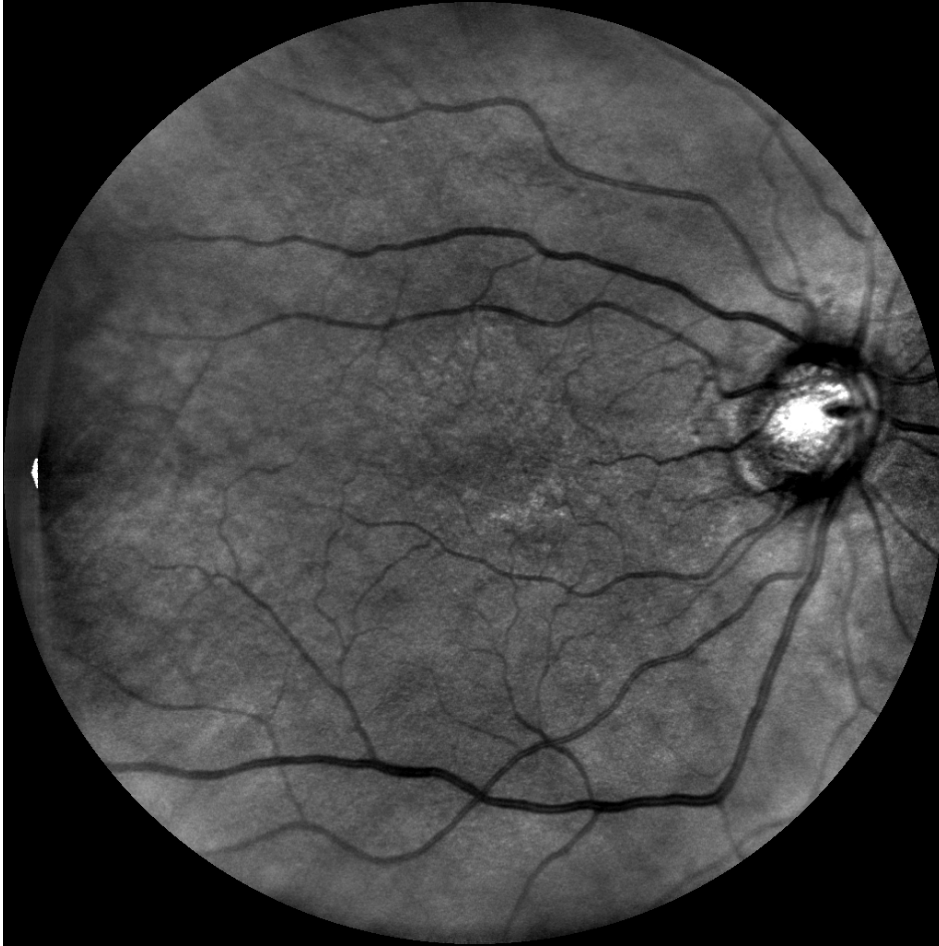Canon cobalt



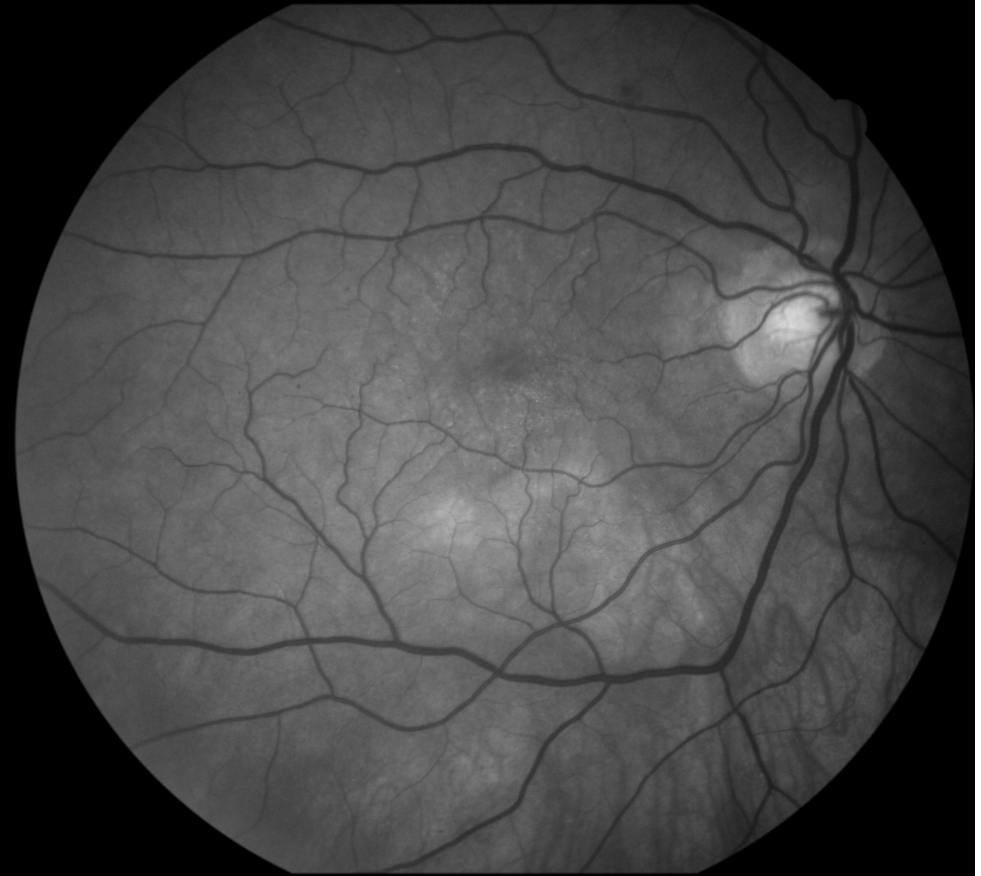

# Female, age 69, glaucoma, diabetic maculopathy, cataract

EasyScan near infrared

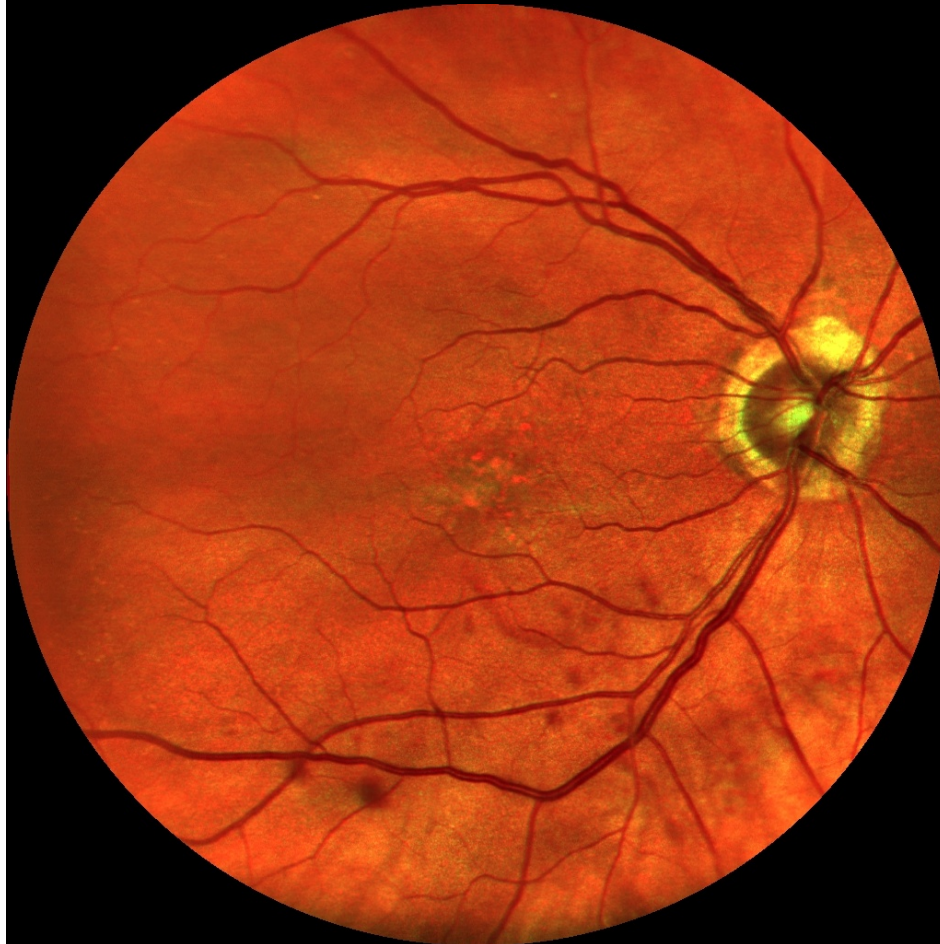

Canon green

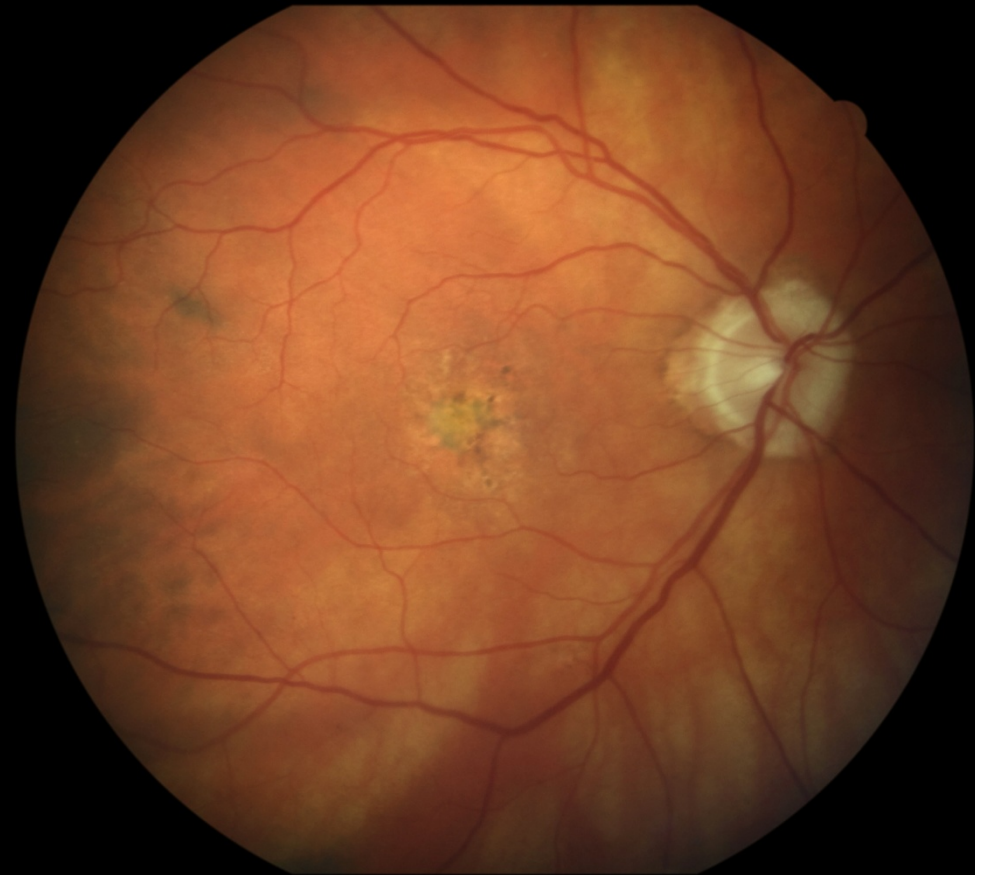

# Female, age 85, glaucoma, AMD, IOL

EasyScan



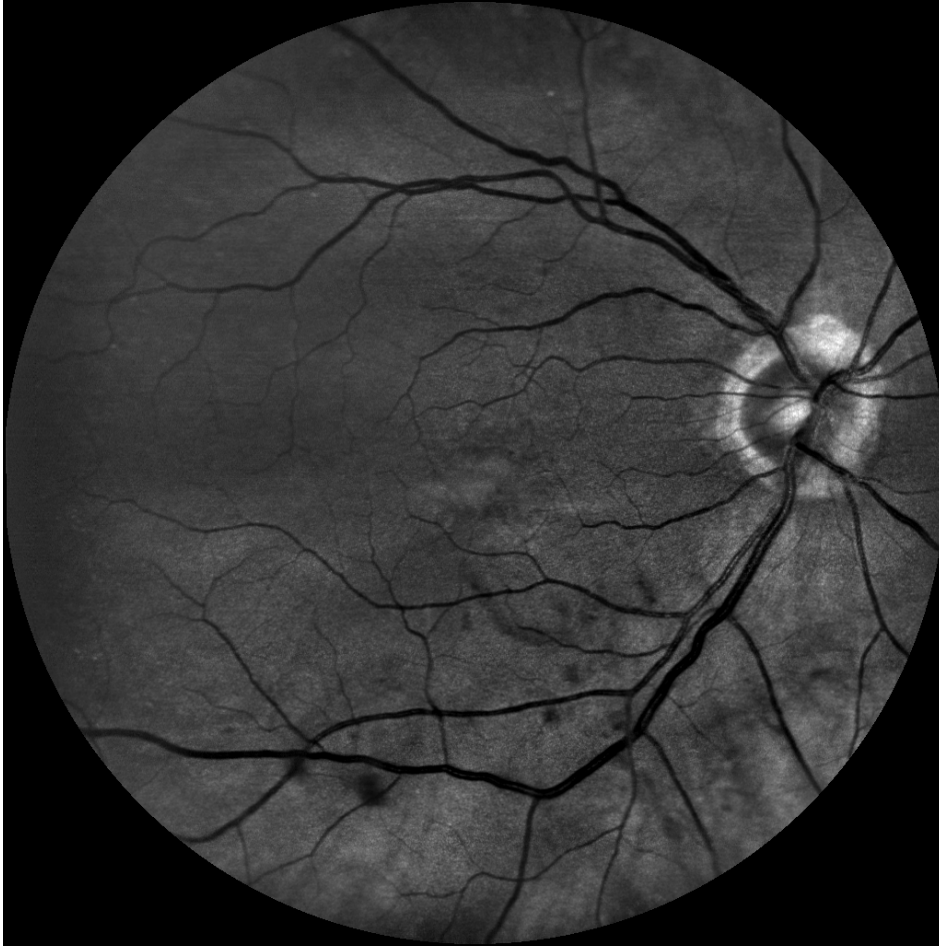Canon



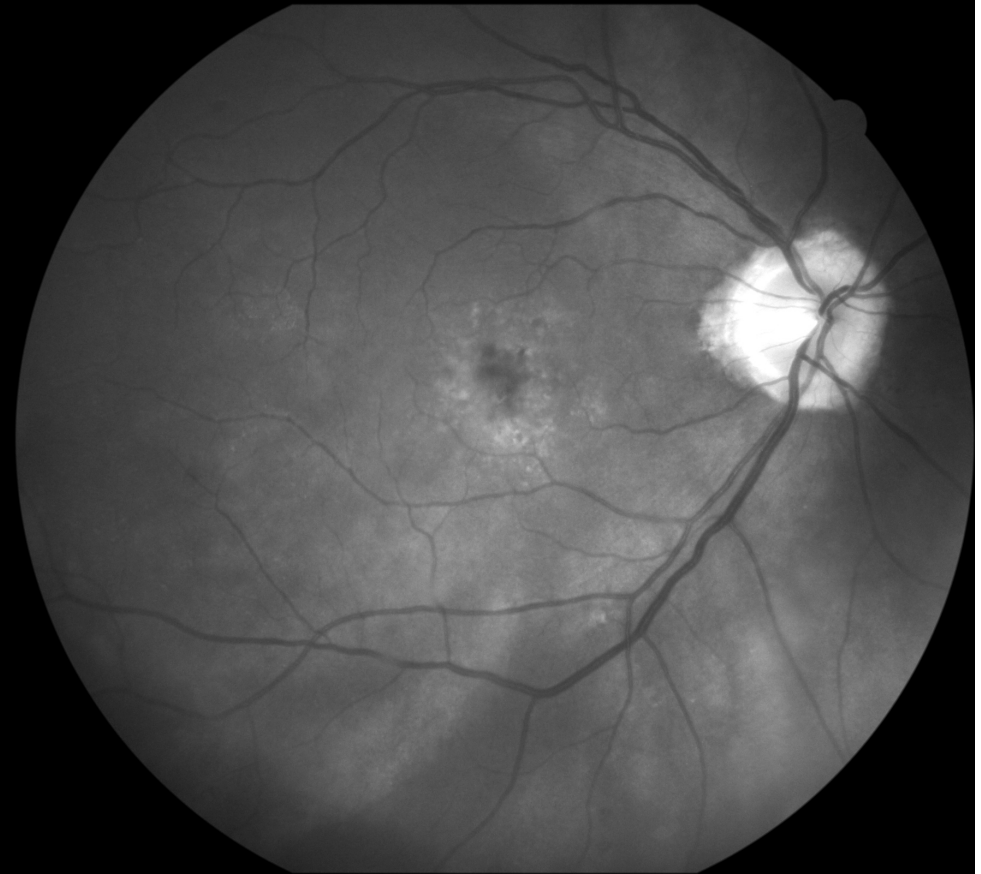


# Female, age 85, glaucoma, AMD, IOL

EasyScan green

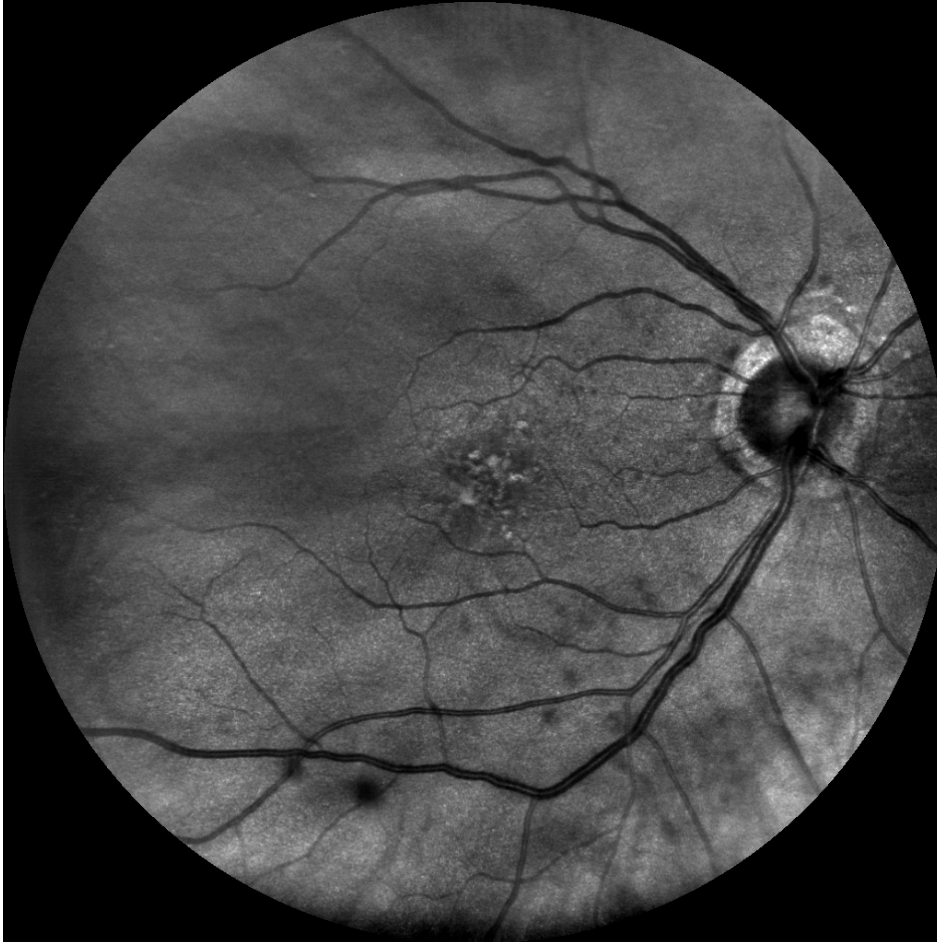


Canon cobalt

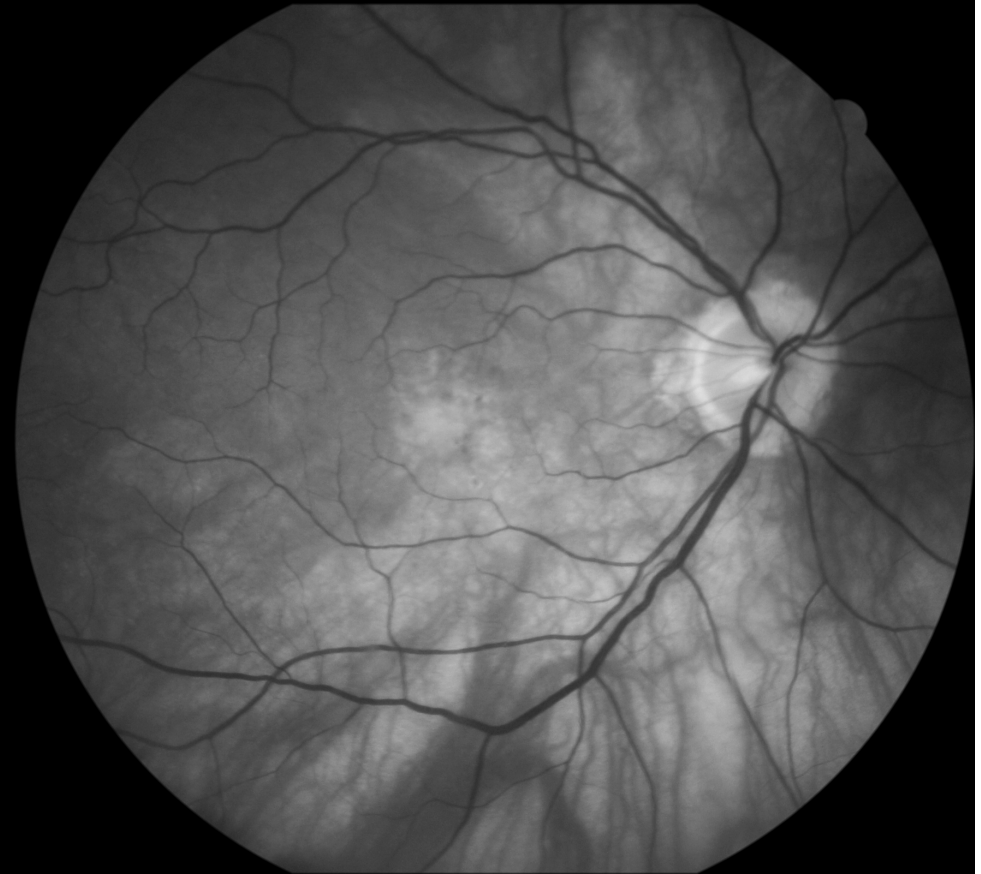

# Female, age 85, glaucoma, AMD, IOL

EasyScan near infrared



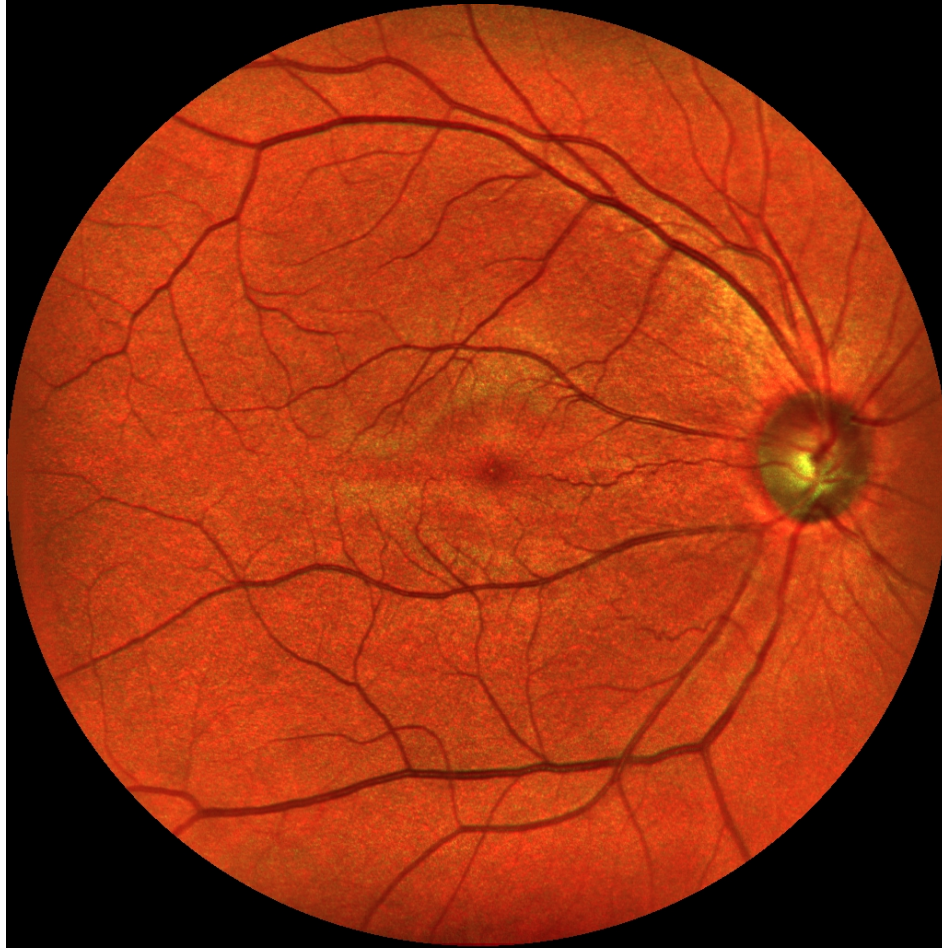
Canon green



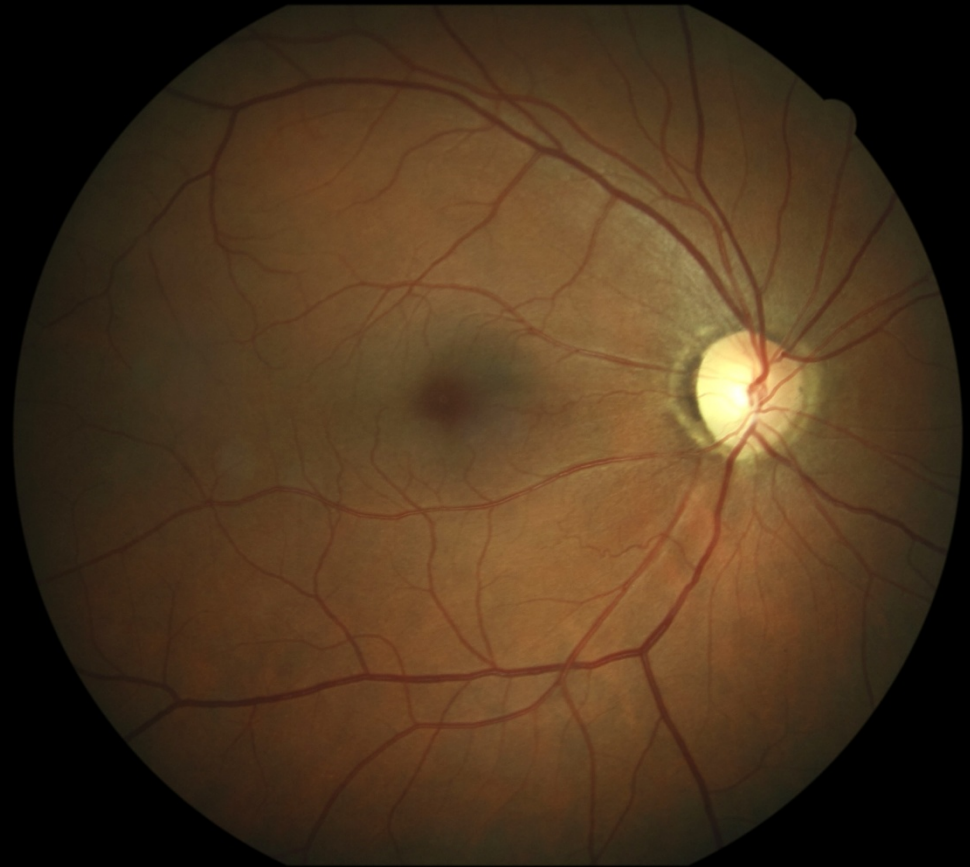


# Male, age 52, glaucoma

EasyScan

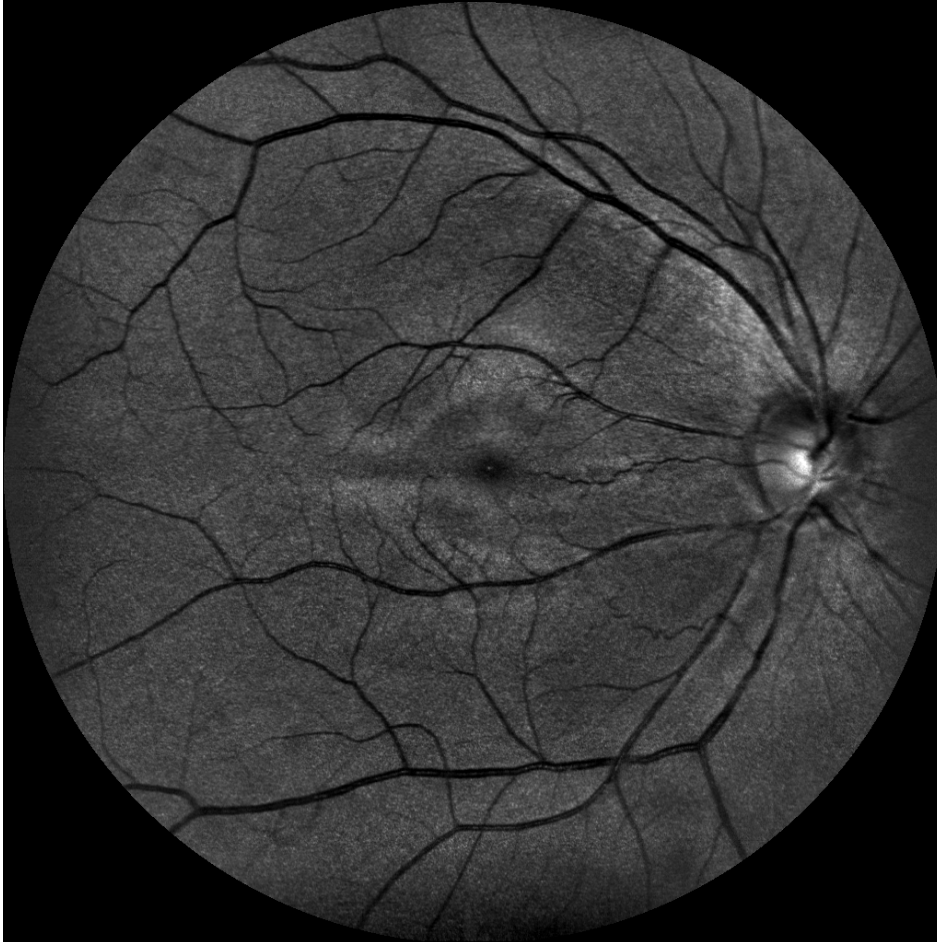

Canon

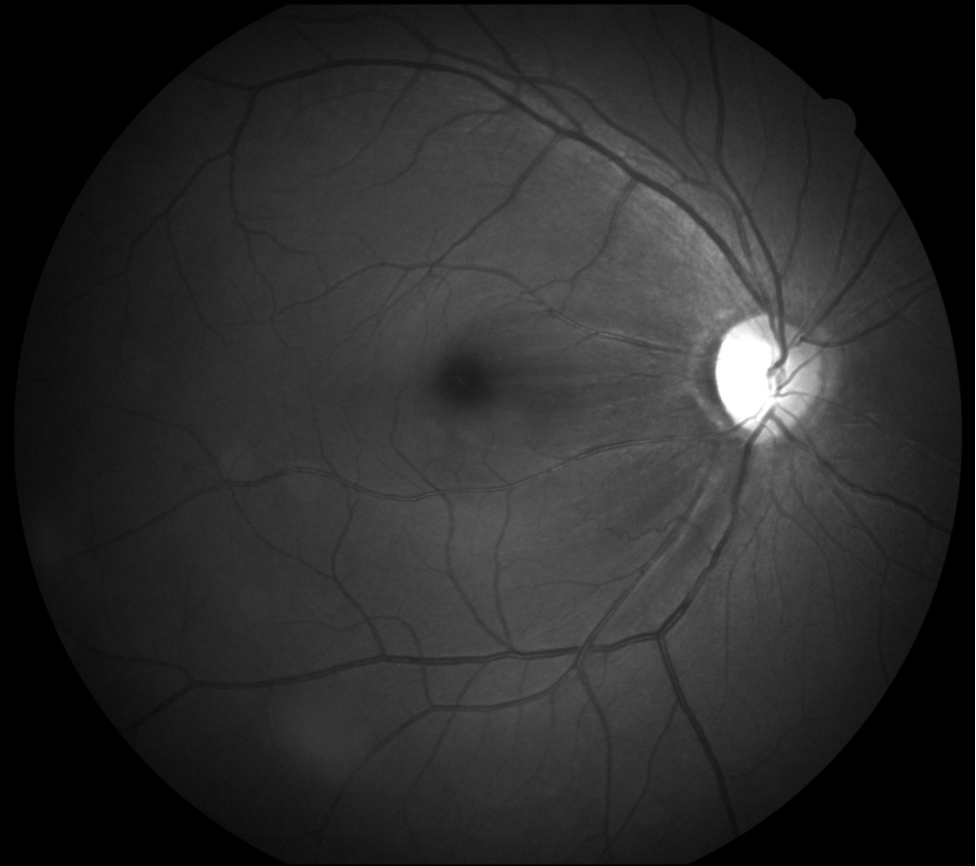


# Male, age 52, glaucoma

EasyScan green



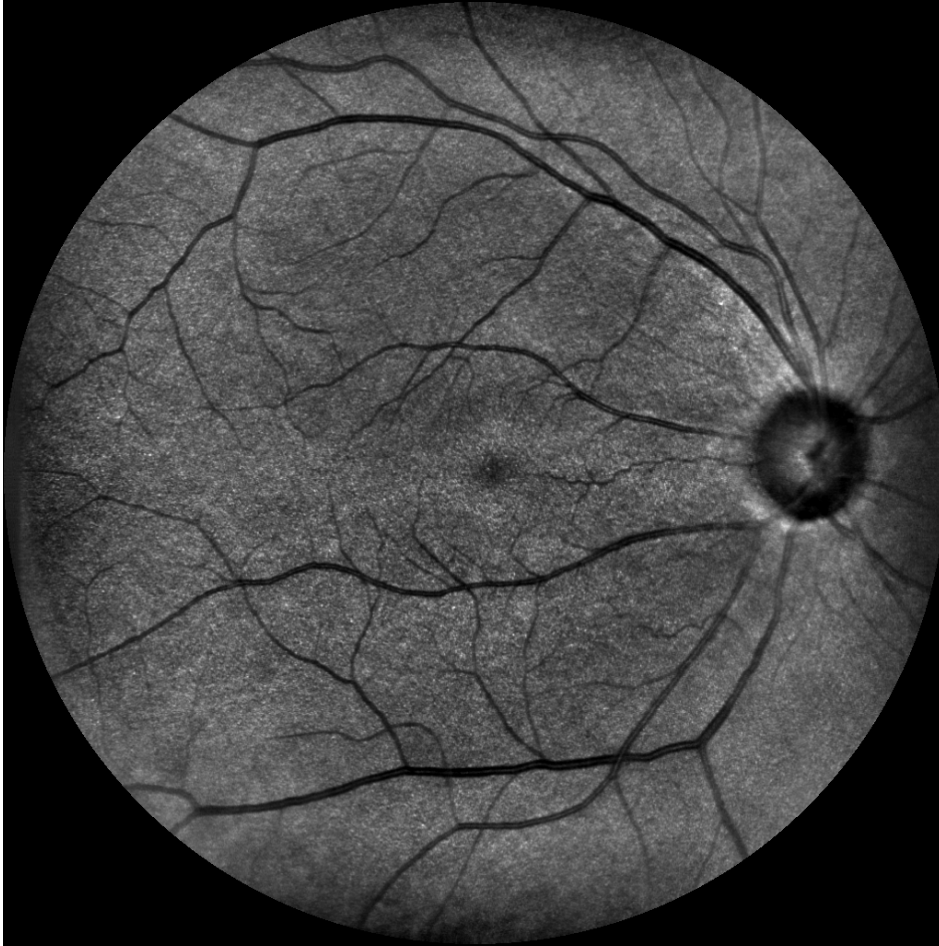Canon cobalt



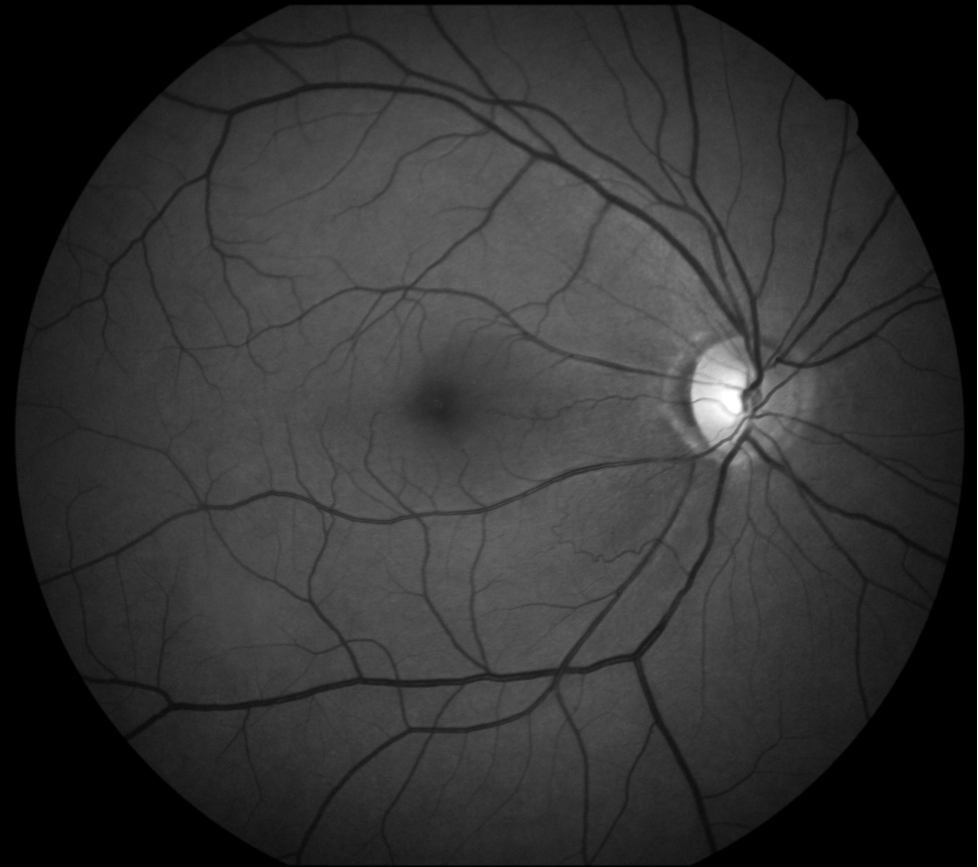

# Male, age 52, glaucoma

EasyScan near infrared

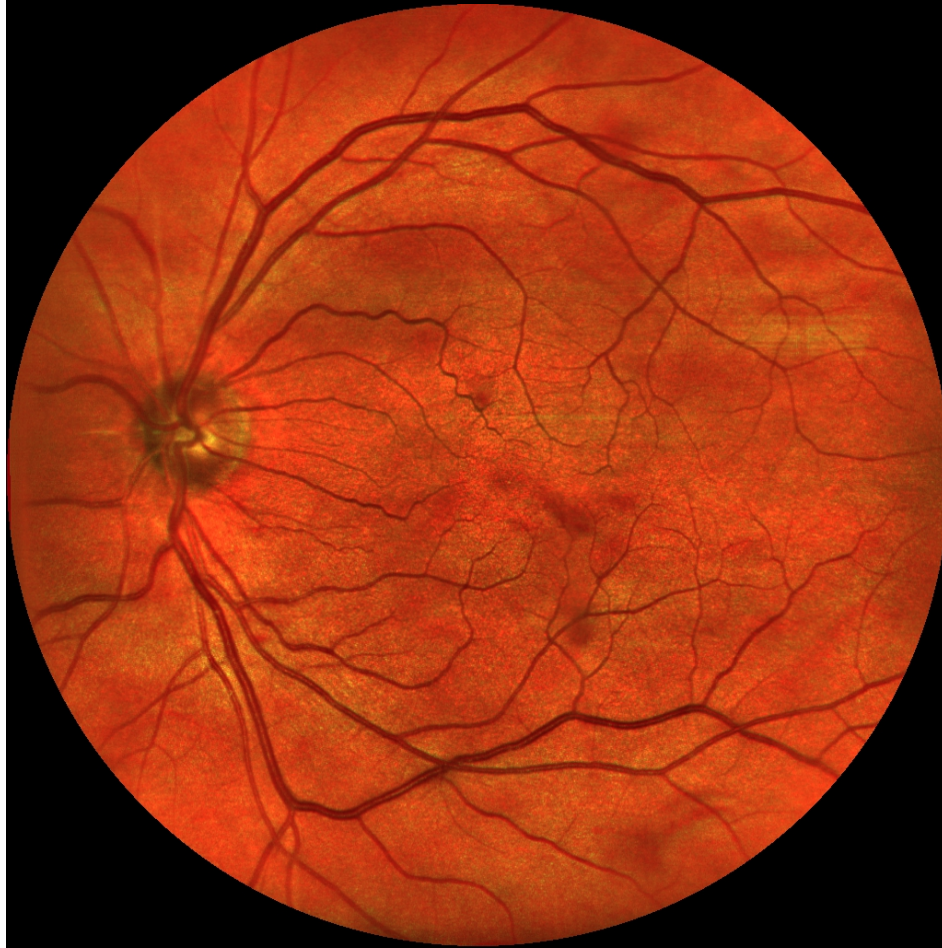

Canon green

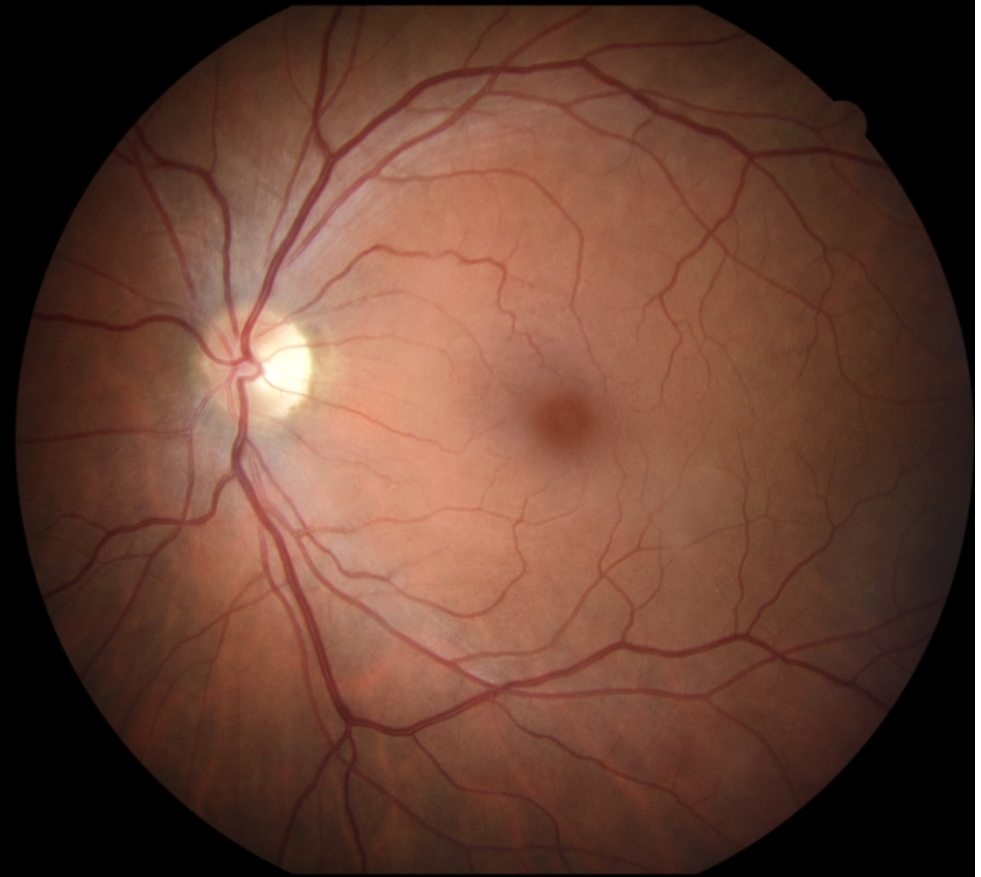

# Female, age 58, glaucoma, IOL

EasyScan



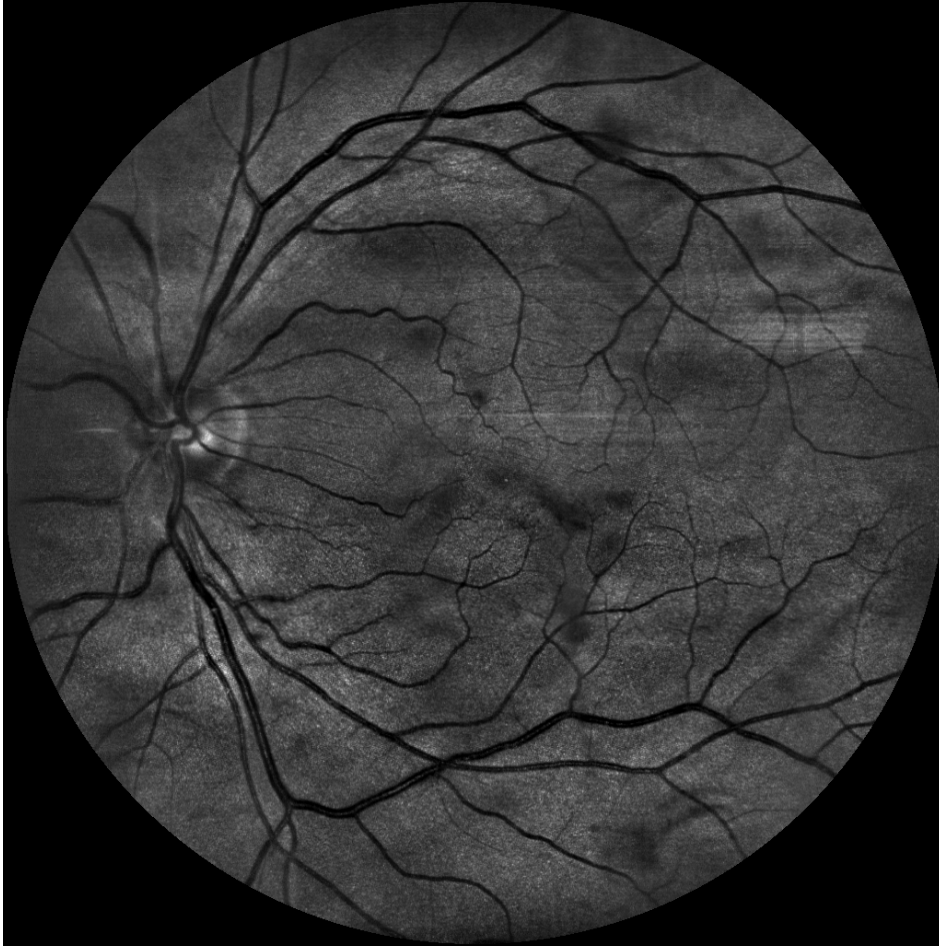Canon



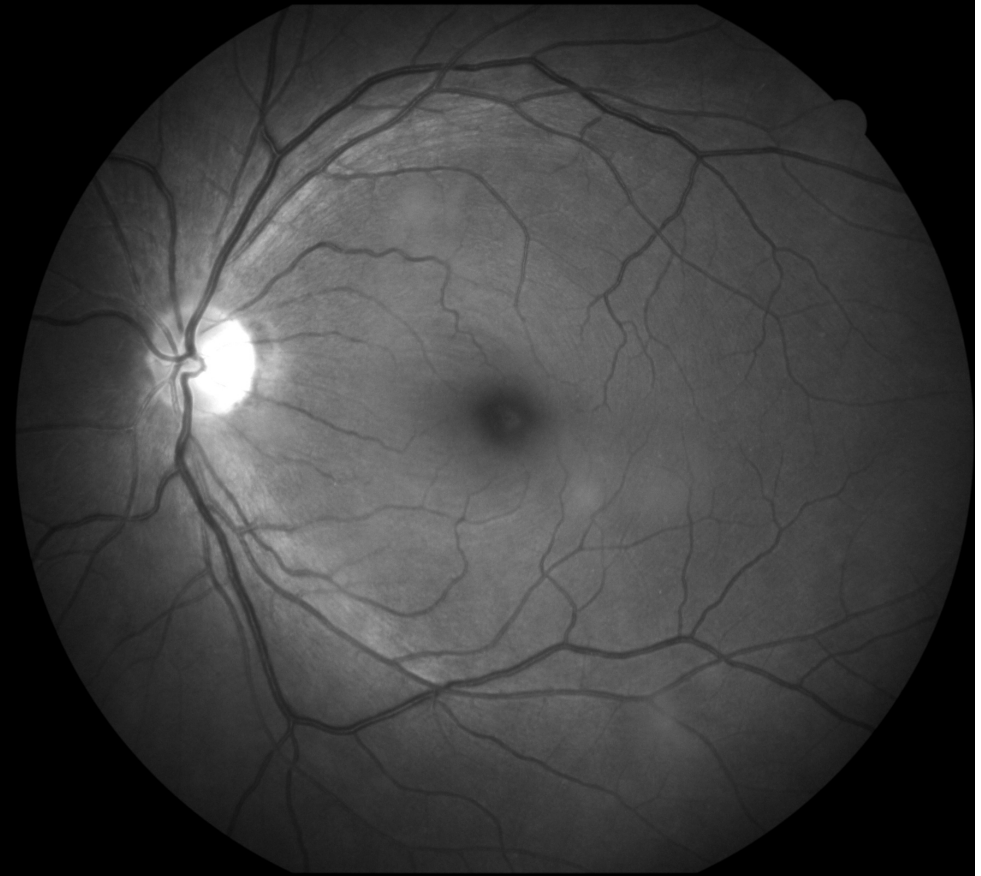


# Female, age 58, glaucoma, IOL

EasyScan green

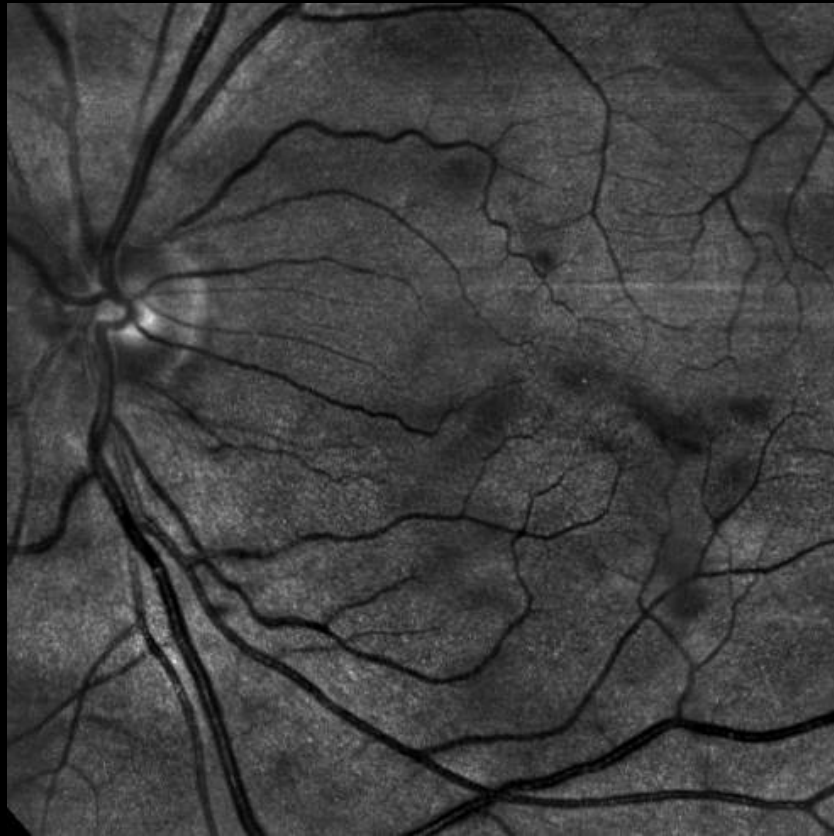

Canon cobalt

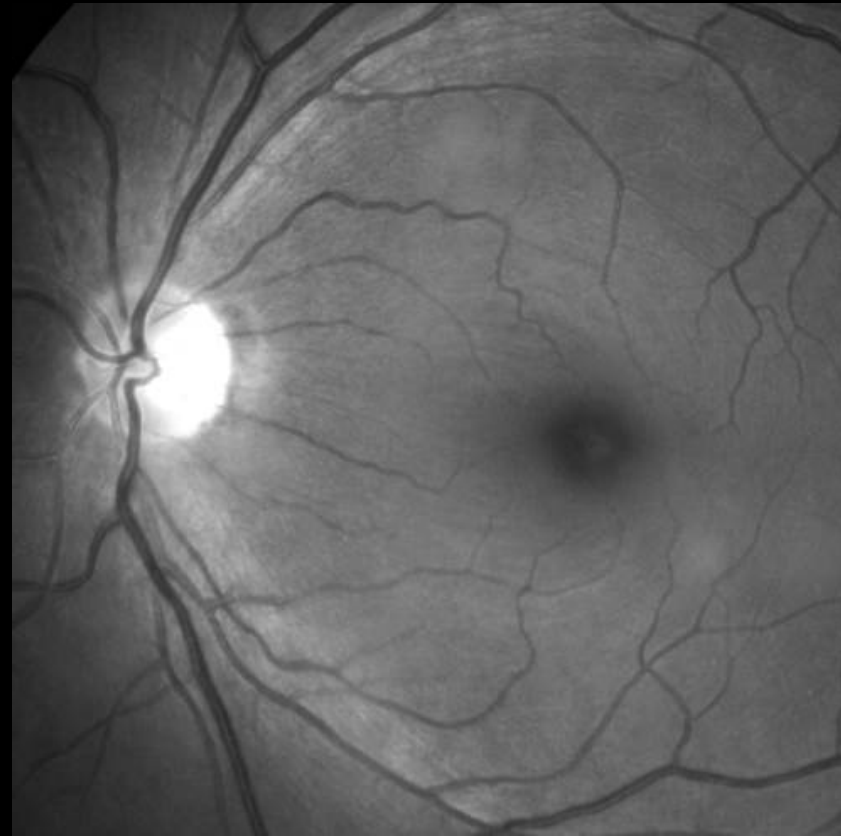

# Female, age 58, glaucoma, IOL

EasyScan green

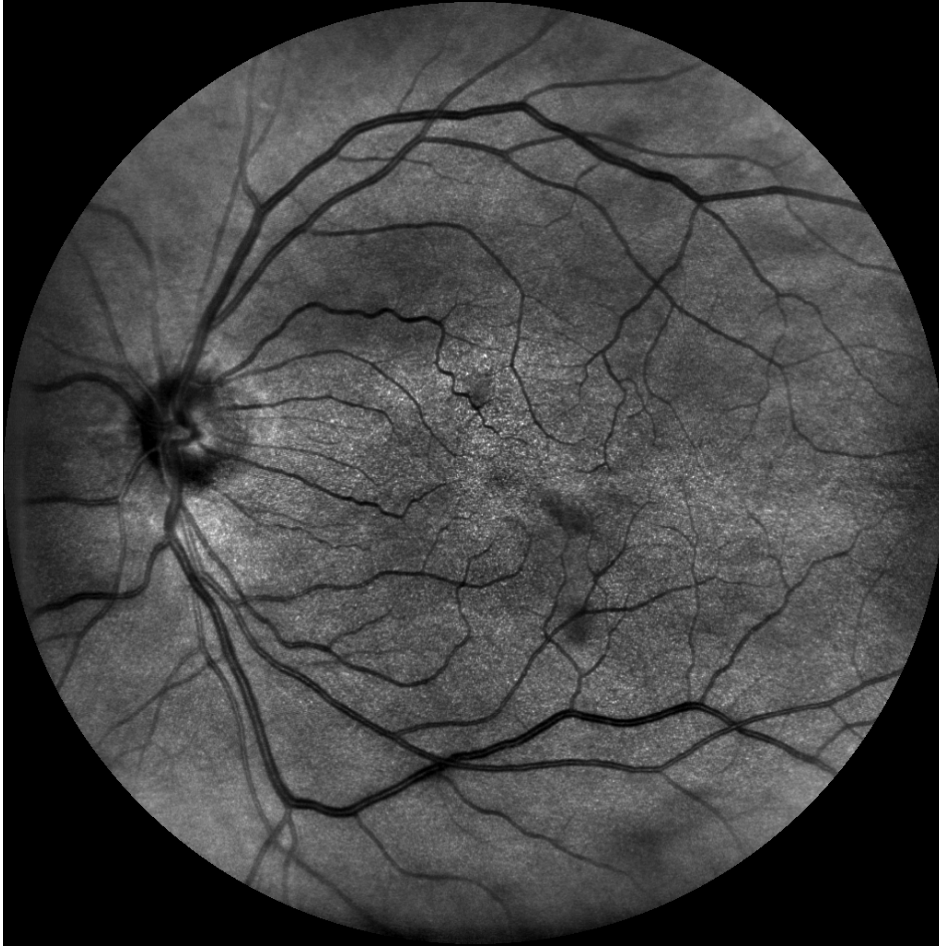

Canon cobalt

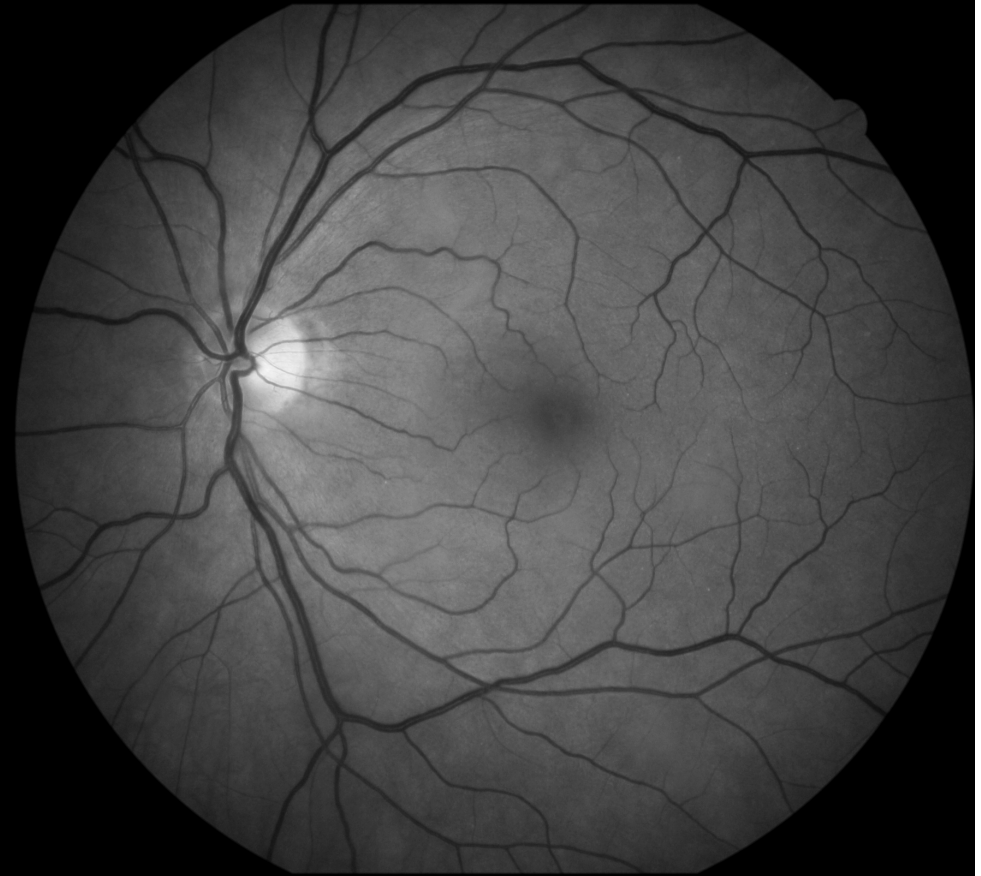

# Female, age 58, glaucoma, IOL

EasyScan near infrared



Canon green

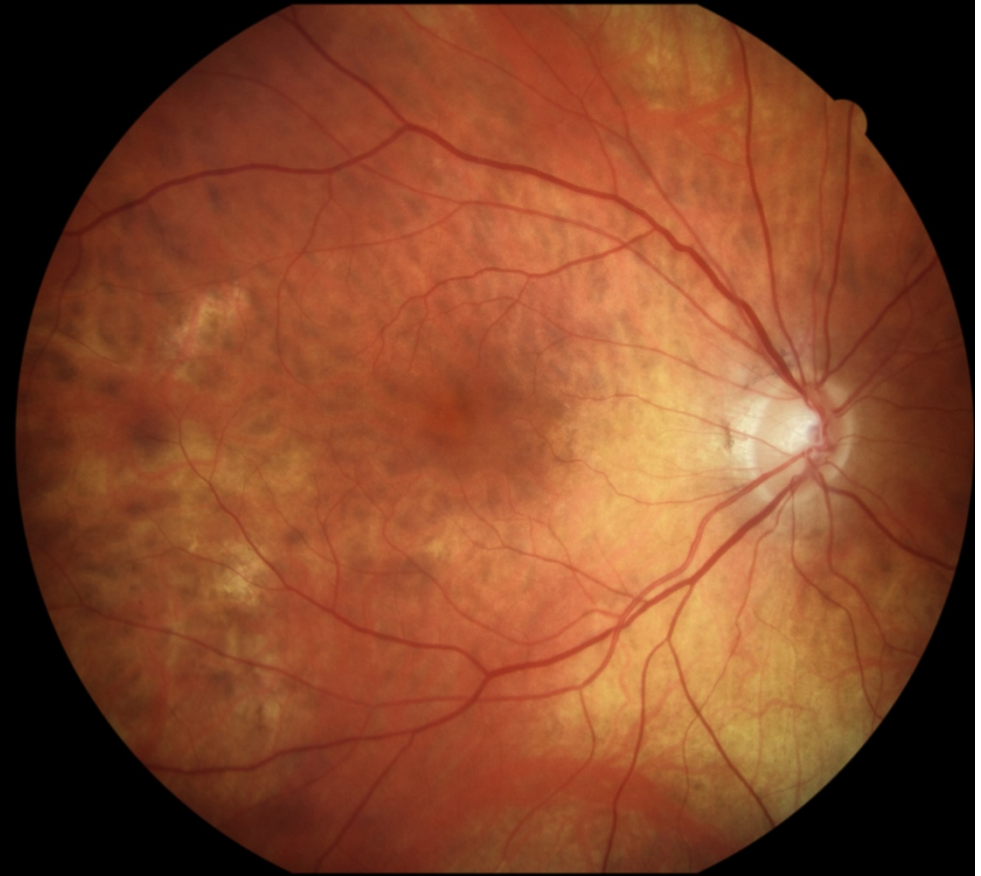
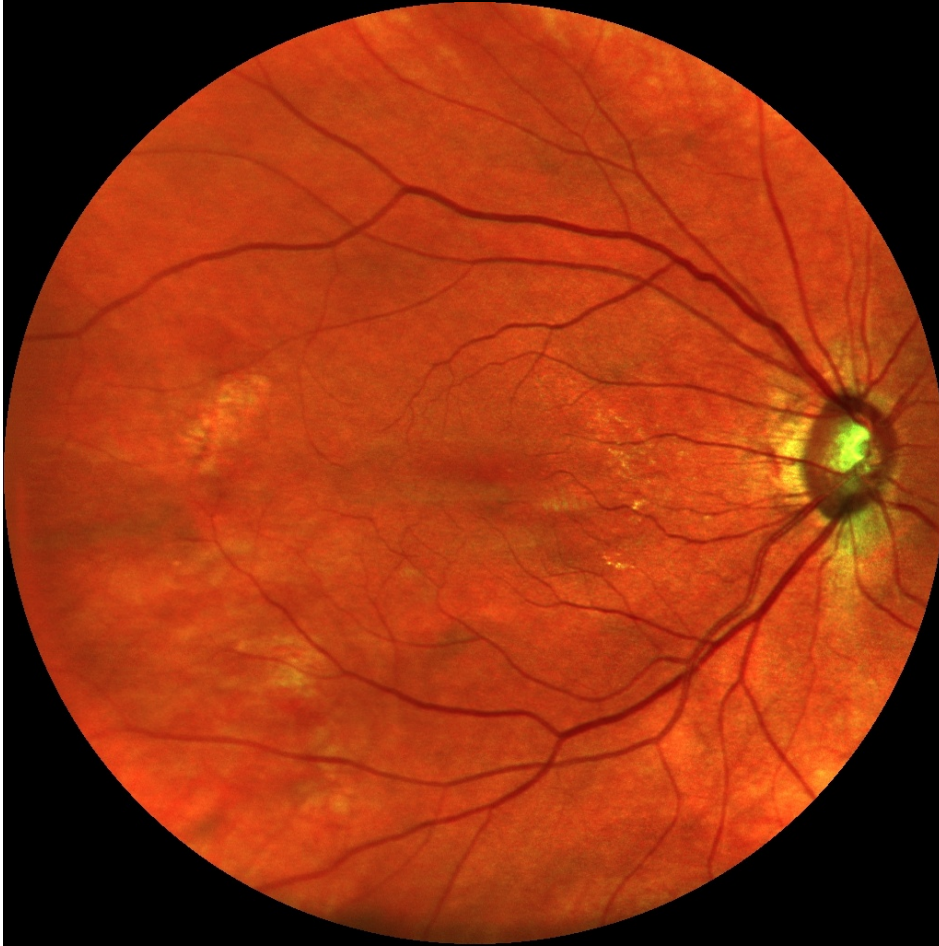



# Female, age 68, glaucoma, IOL

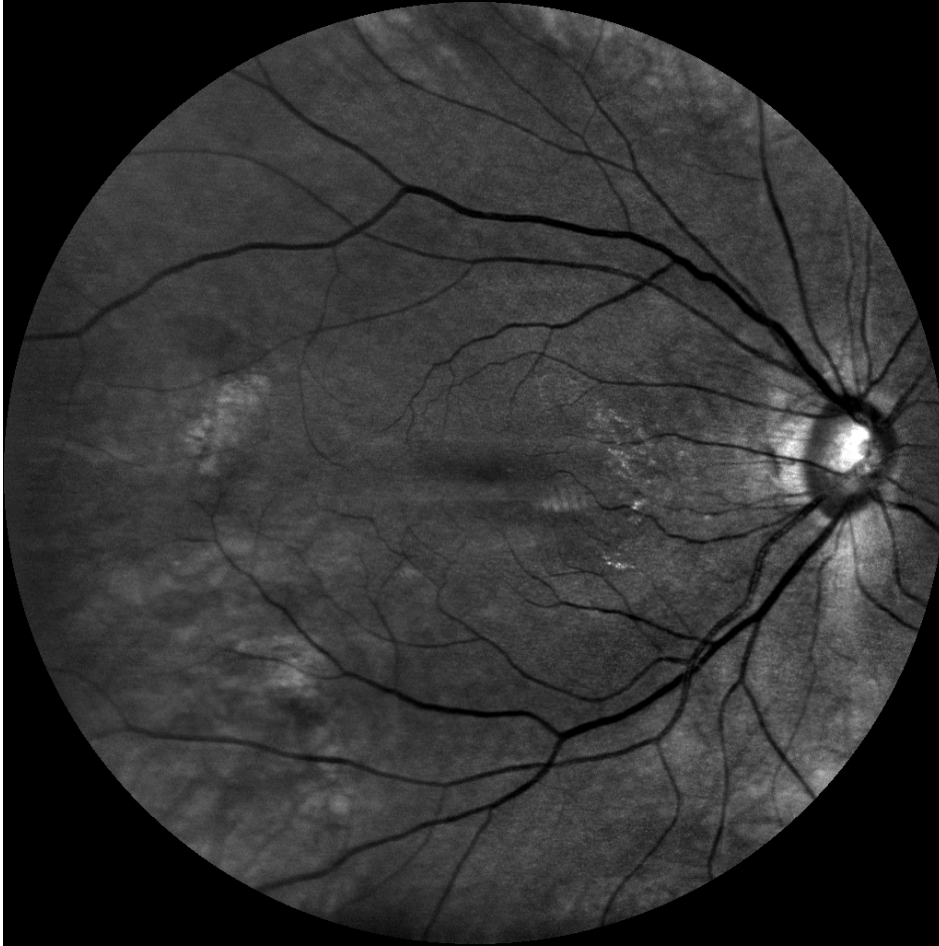EasyScan

Canon

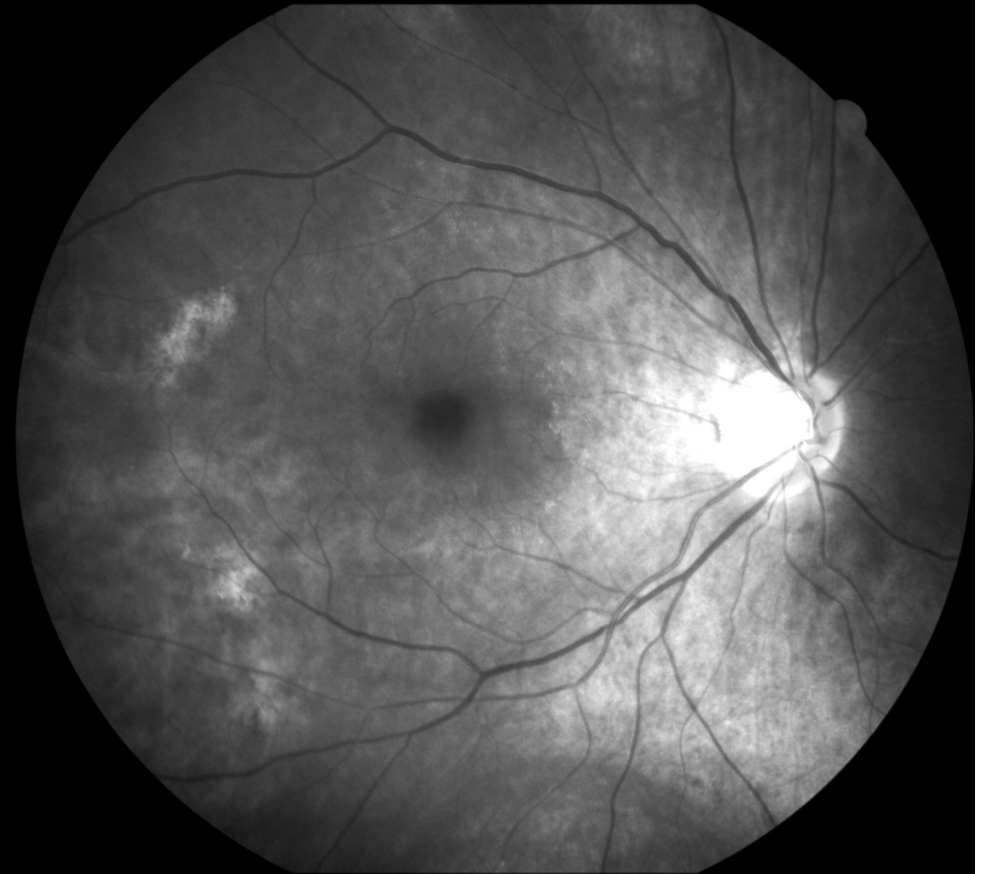


# Female, age 68, glaucoma, IOL

EasyScan green



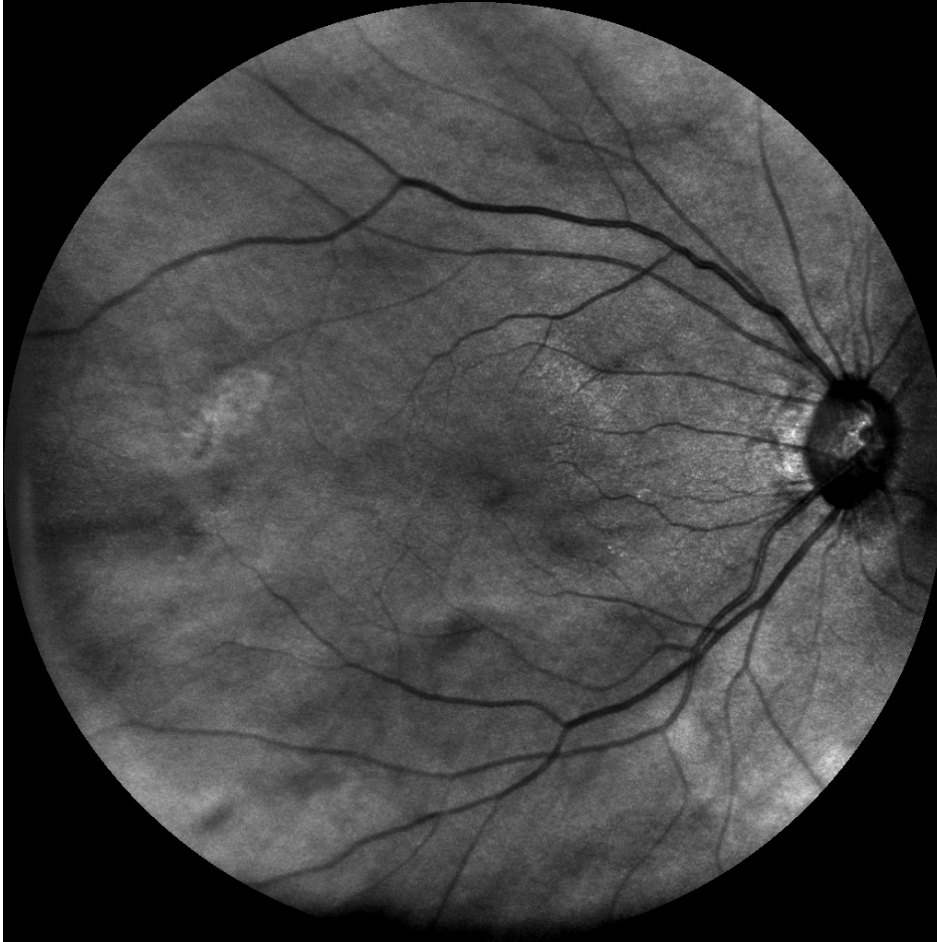Canon cobalt



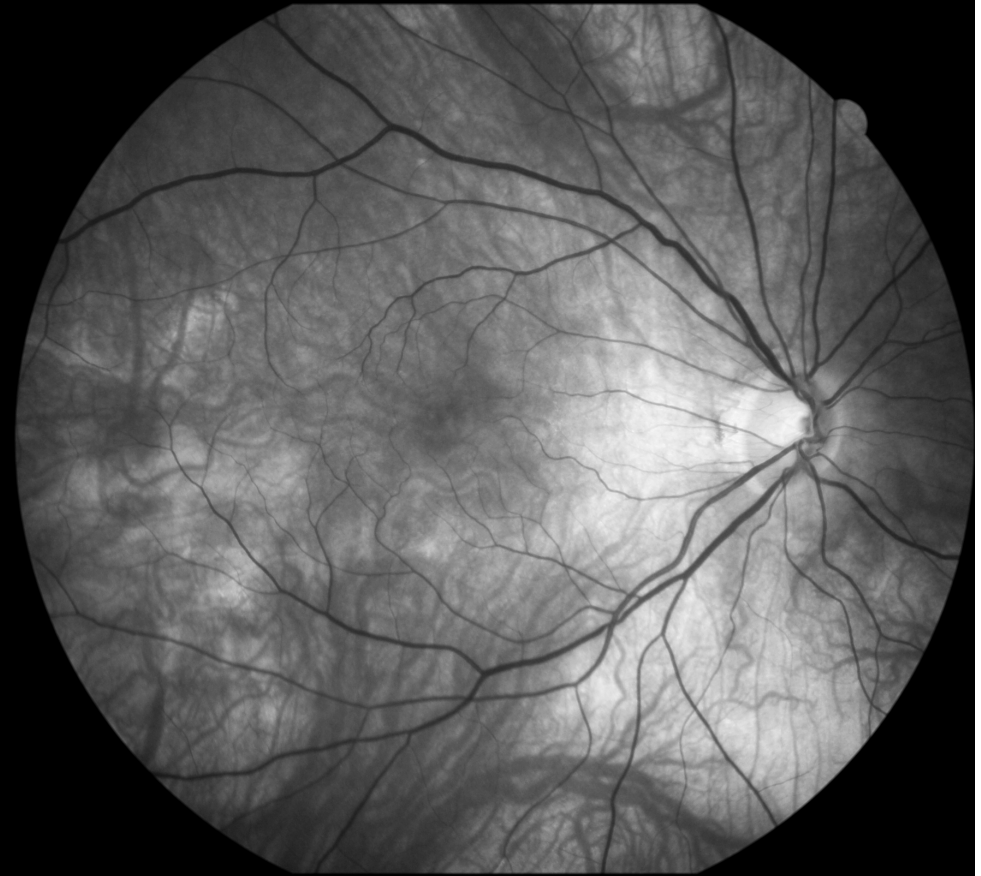


# Female, age 68, glaucoma, IOL

EasyScan near infrared



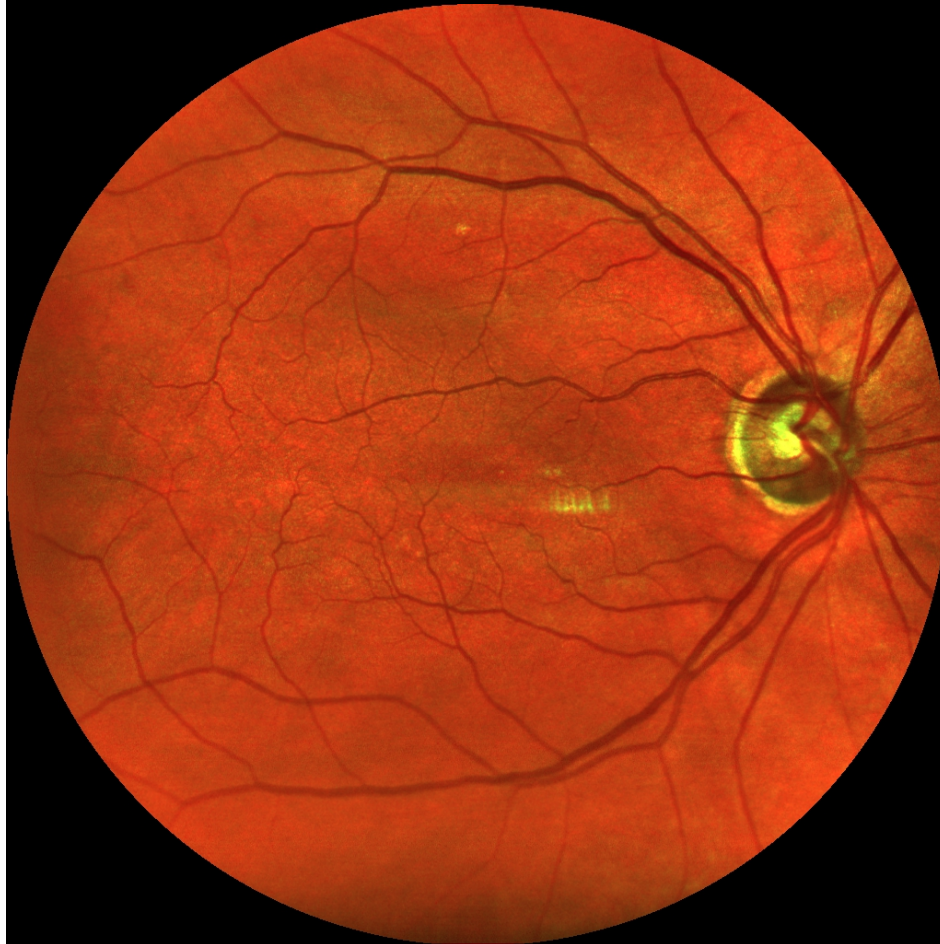
Canon green



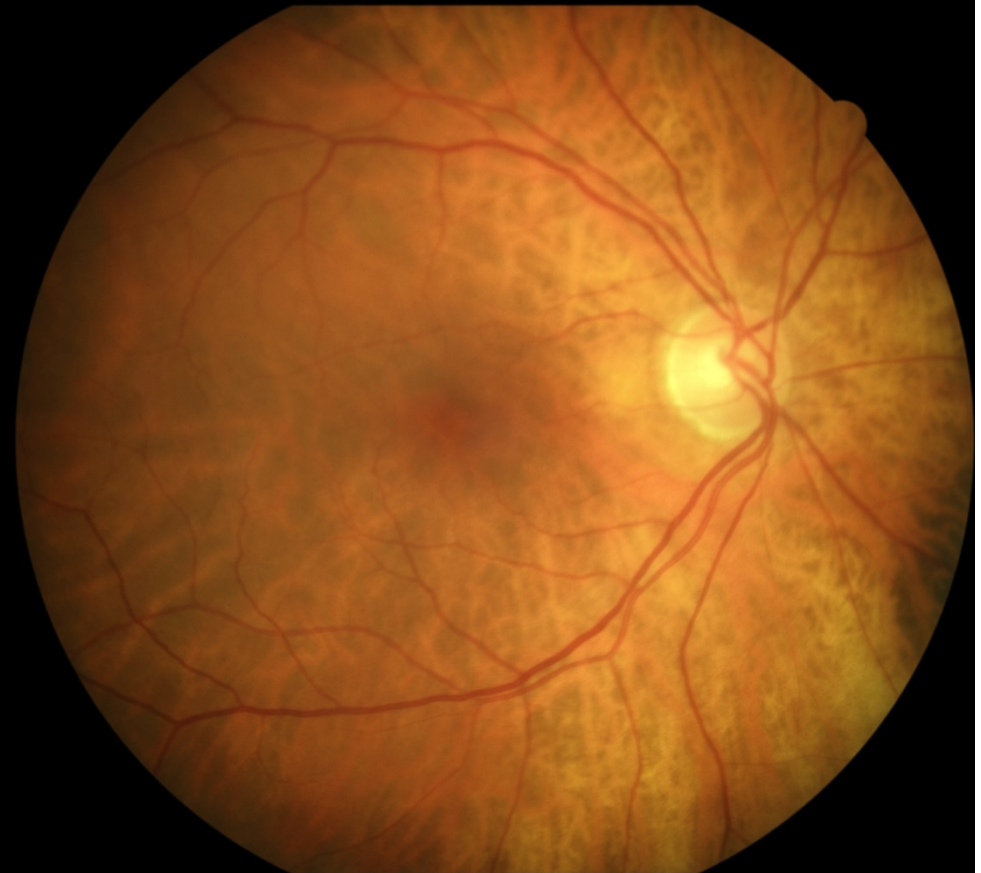


# Female, age 69, glaucoma

EasyScan

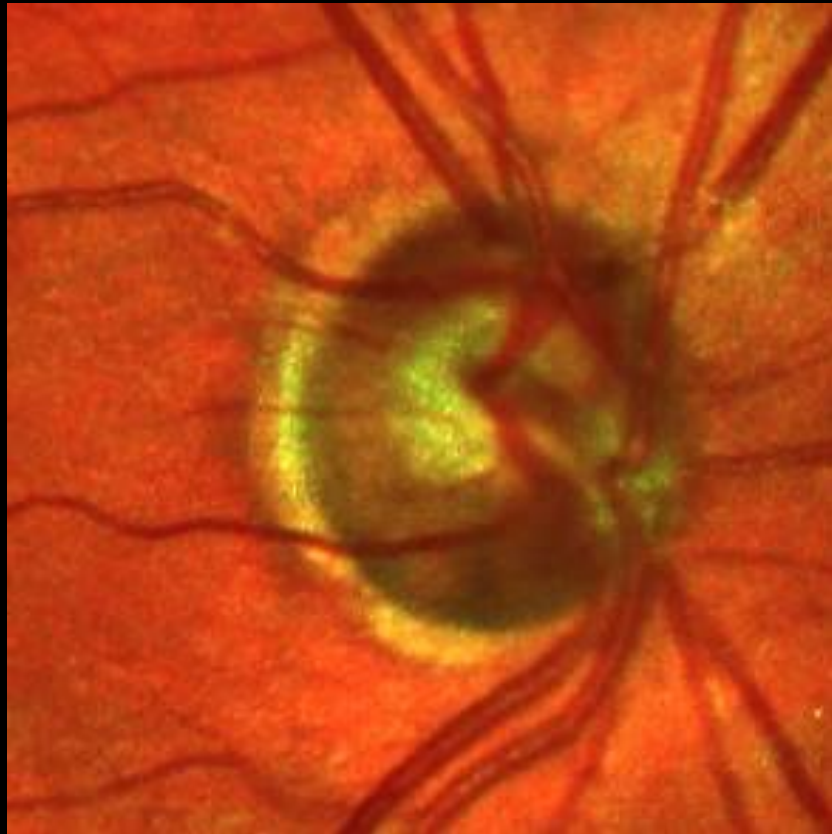

Canon

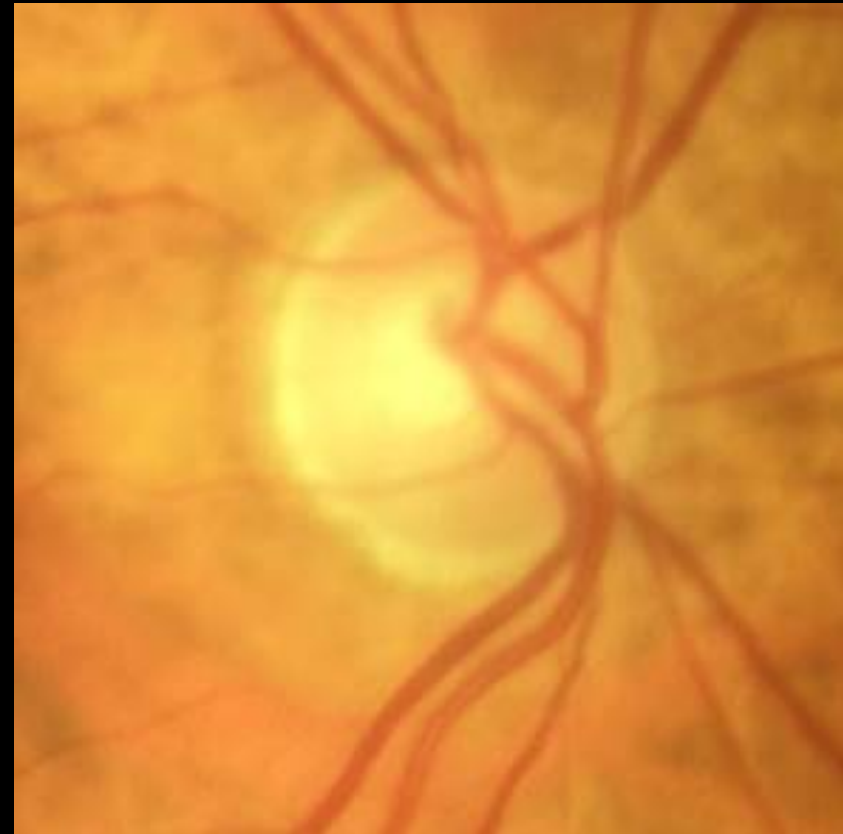

# Female, age 69, glaucoma

EasyScan



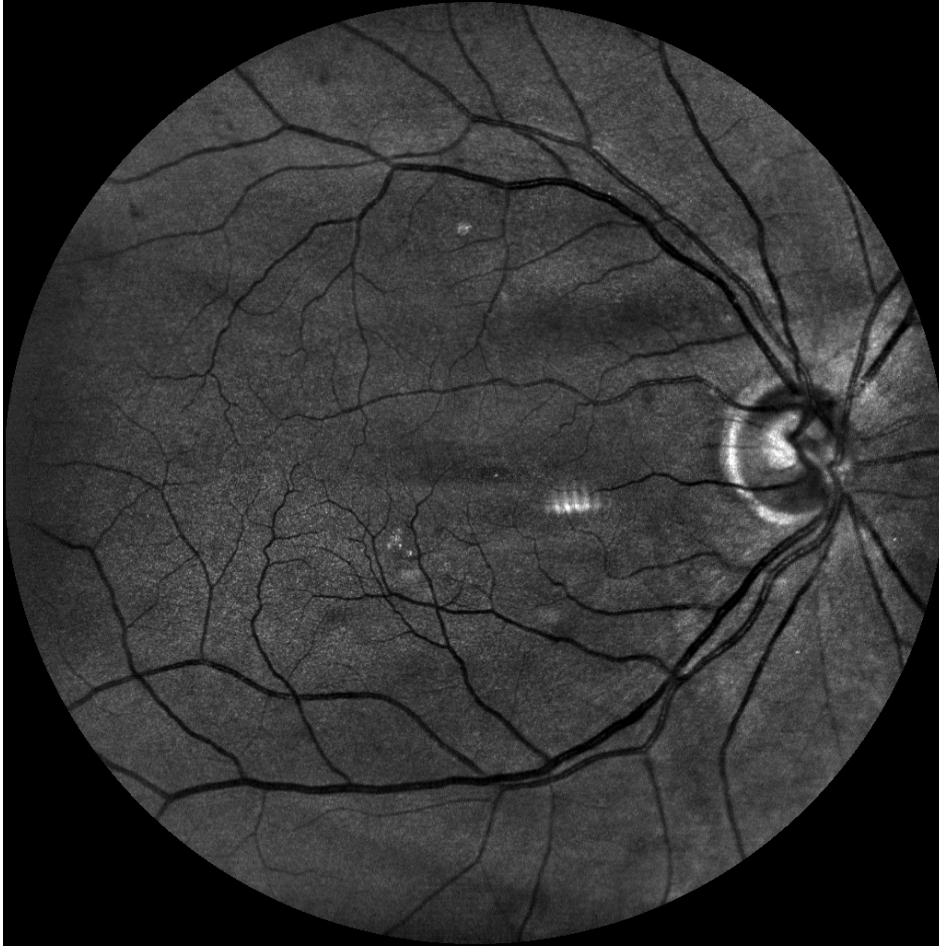Canon



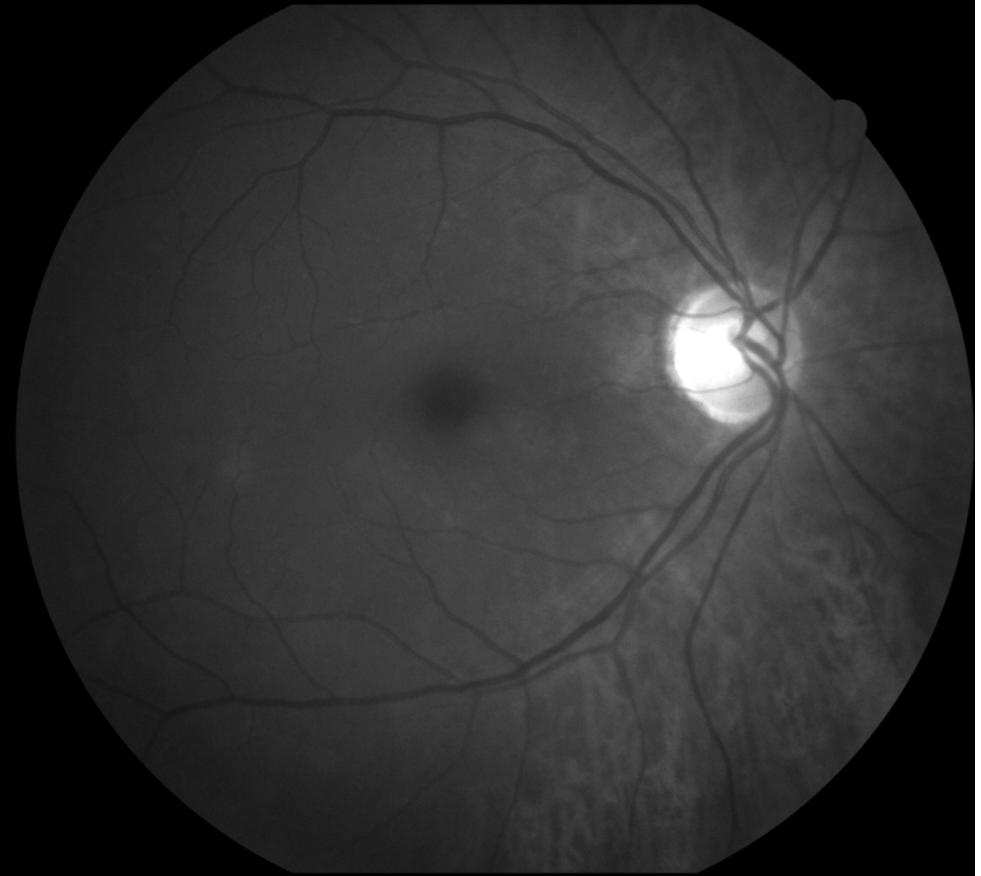


# Female, age 69, glaucoma

EasyScan green



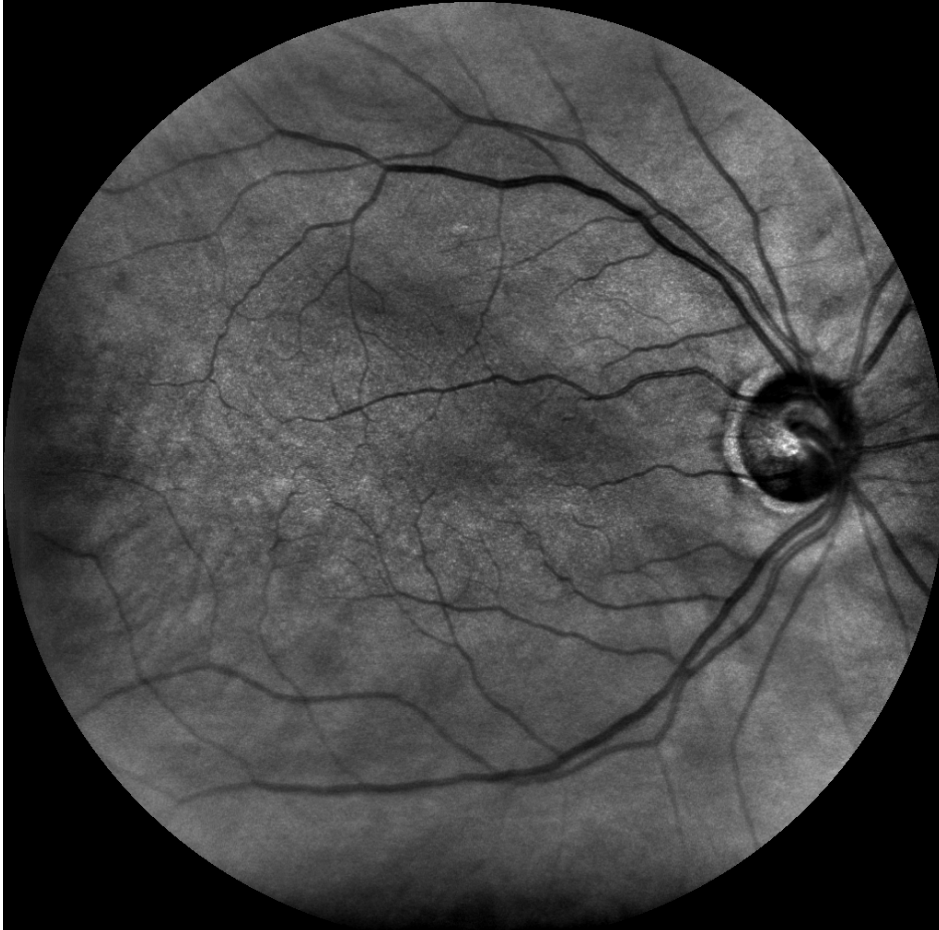
Canon cobalt



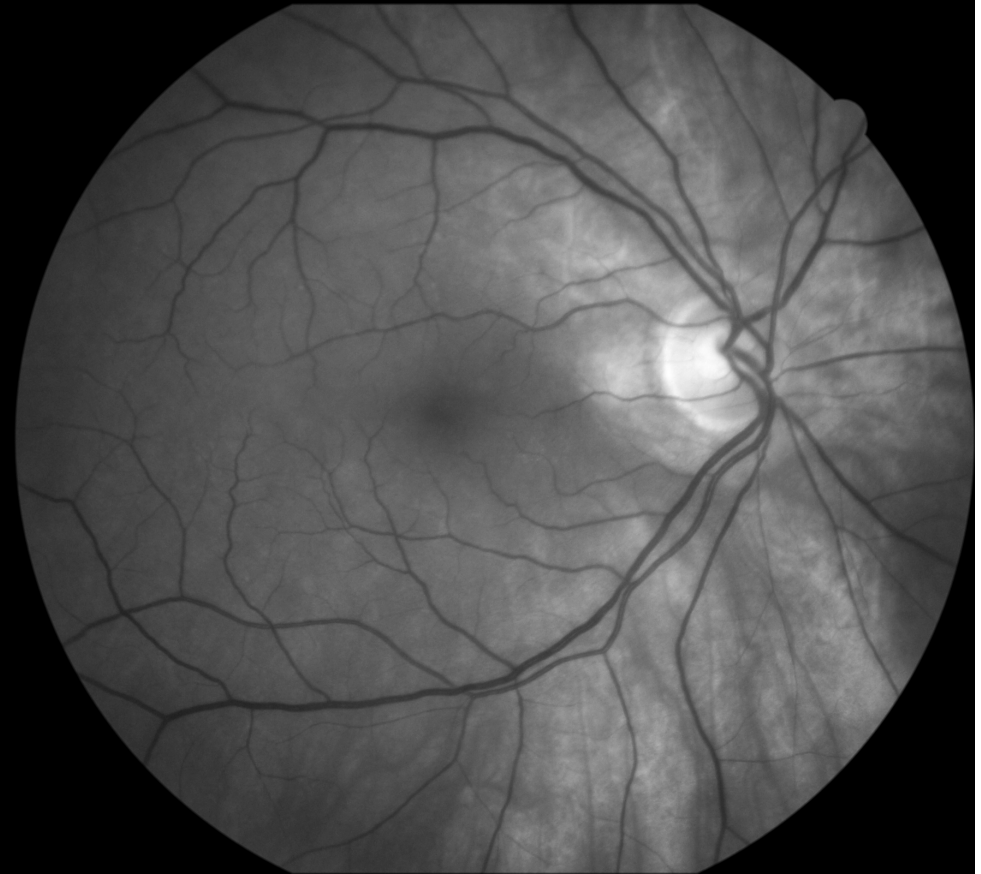


# Female, age 69, glaucoma

EasyScan near infrared

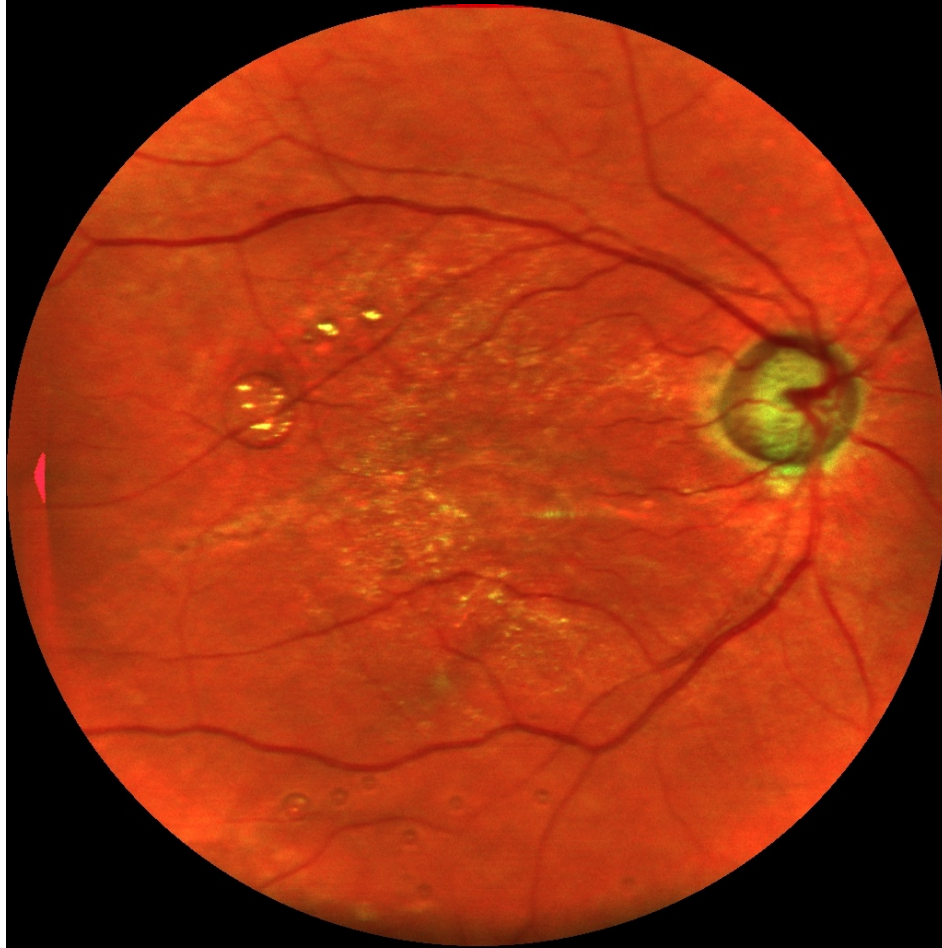


Canon green

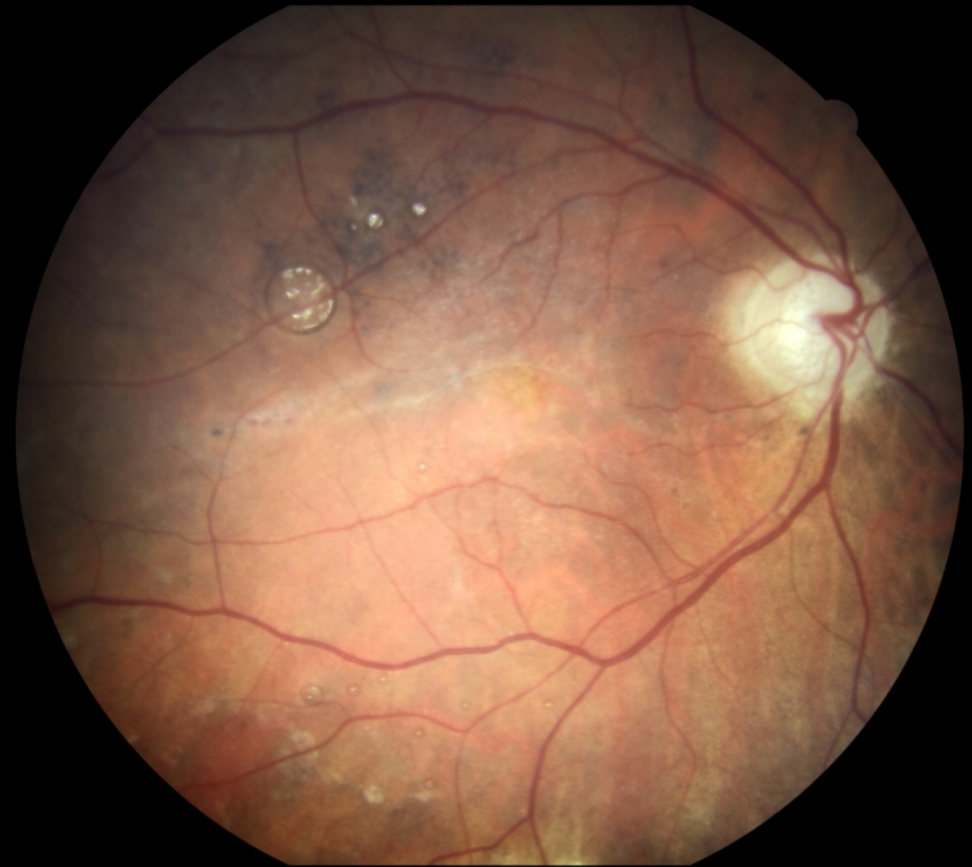

# Female, age 81, glaucoma, retinal detachment

EasyScan



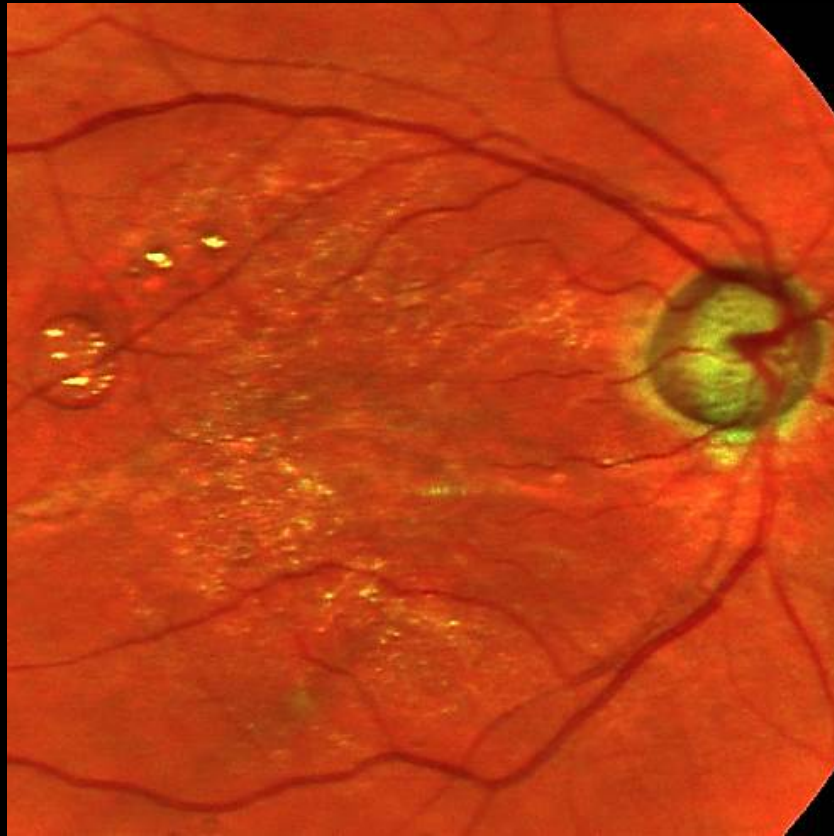
Canon



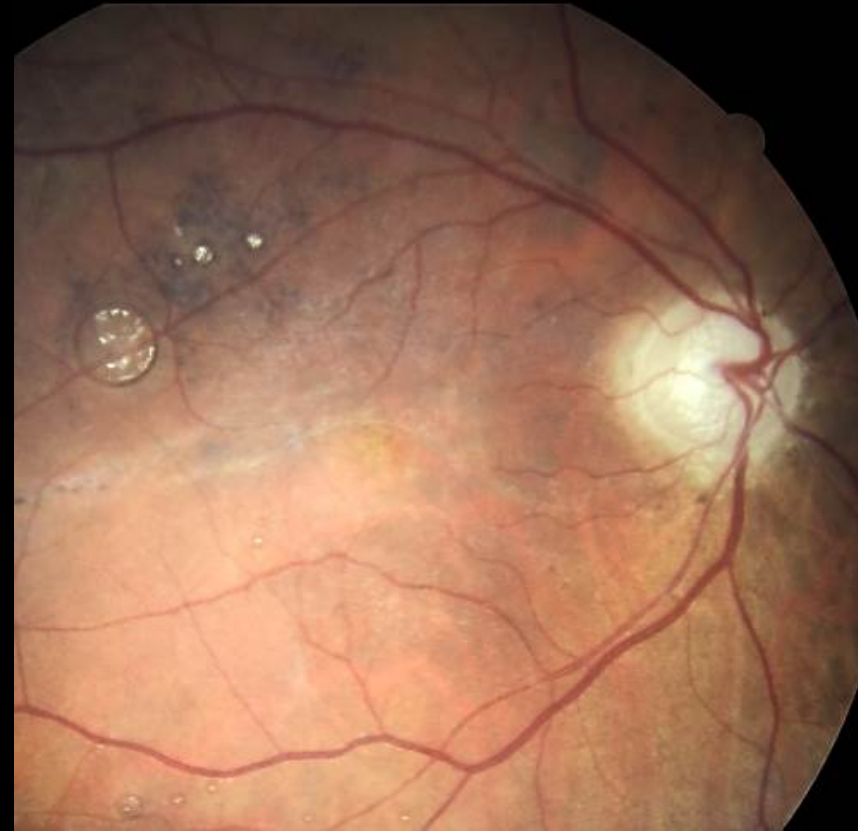

# Female, age 81, glaucoma, retinal detachment

EasyScan



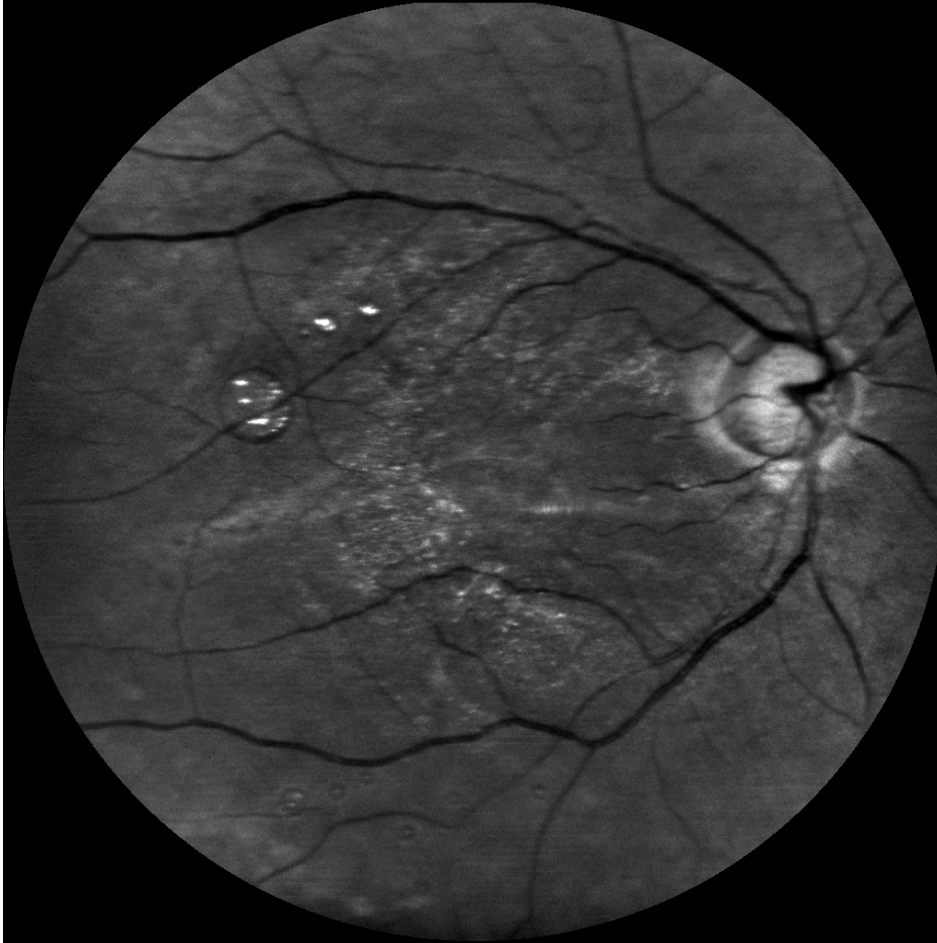
Canon



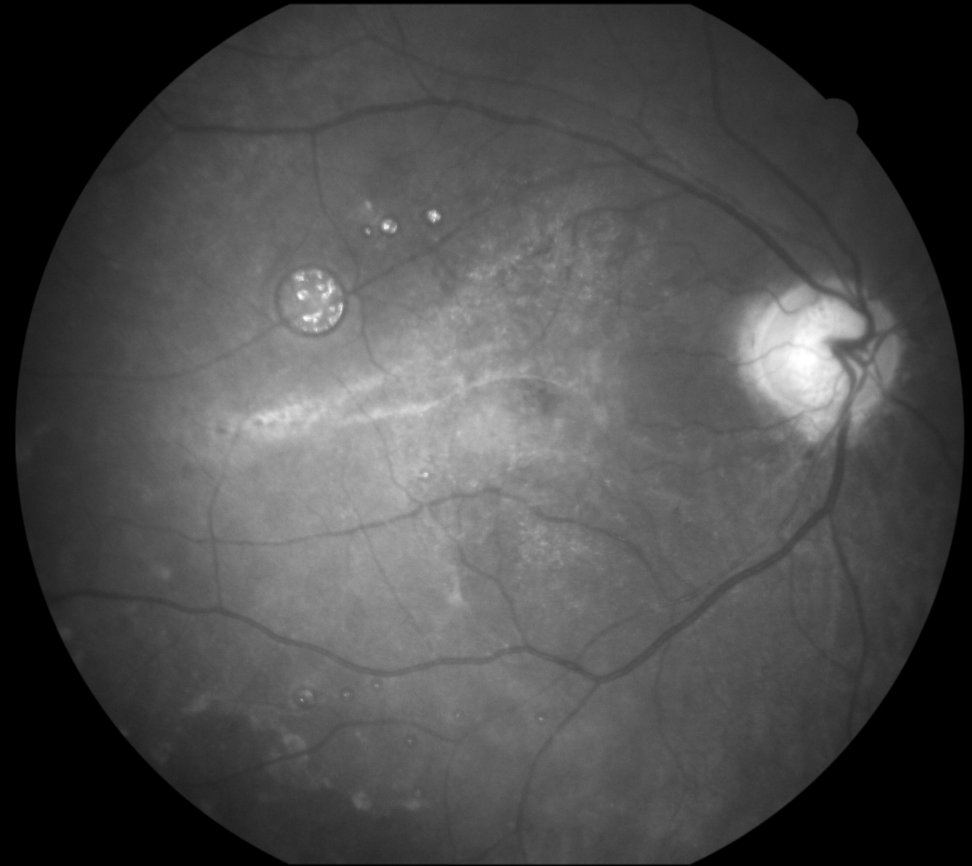


# Female, age 81, glaucoma, retinal detachment

EasyScan green

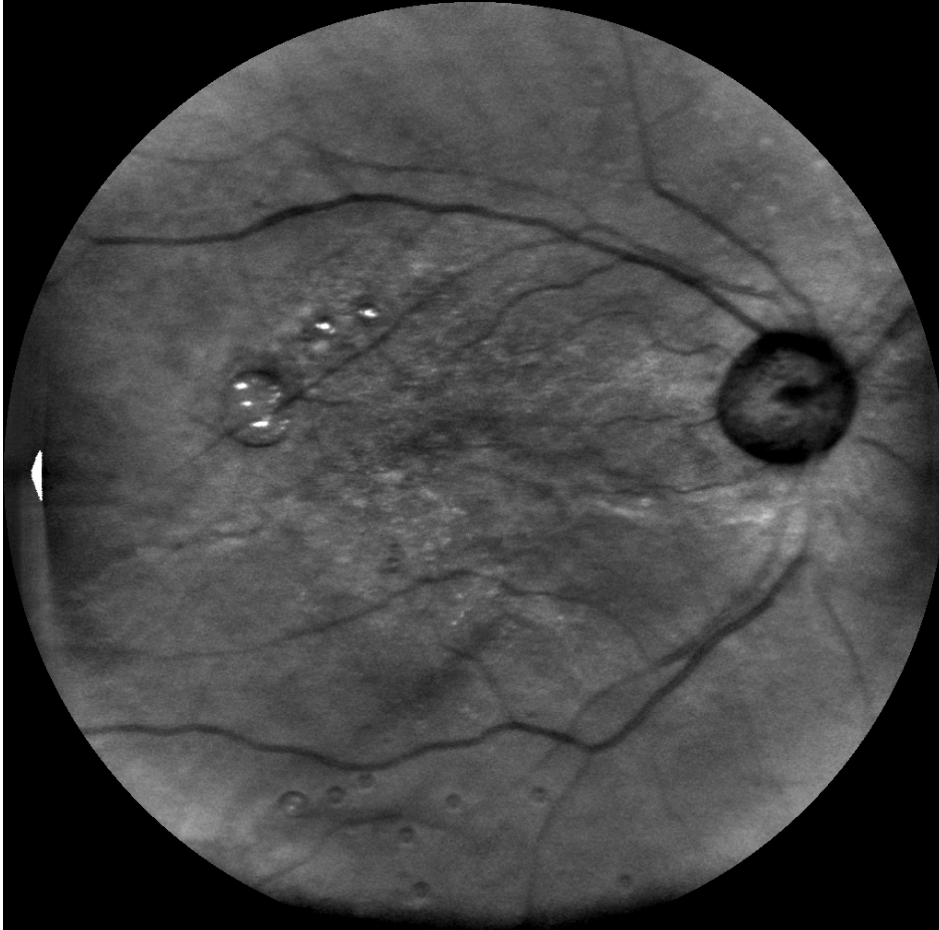

Canon cobalt

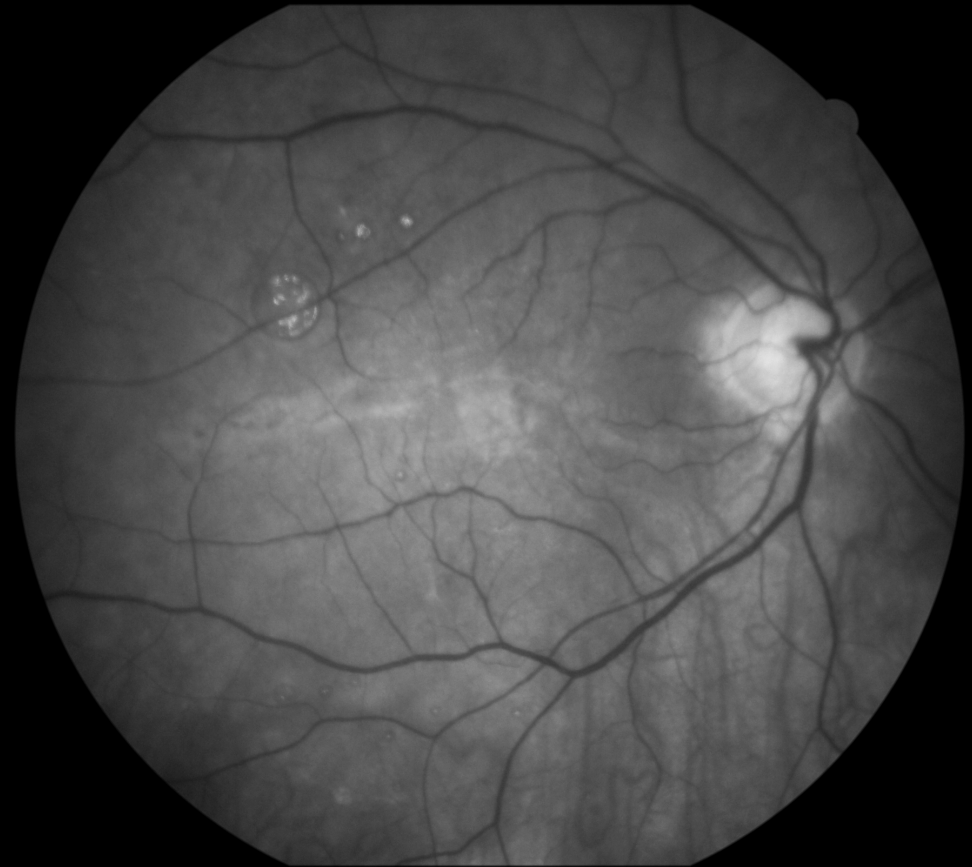


# Female, age 81, glaucoma, retinal detachment

EasyScan near infrared



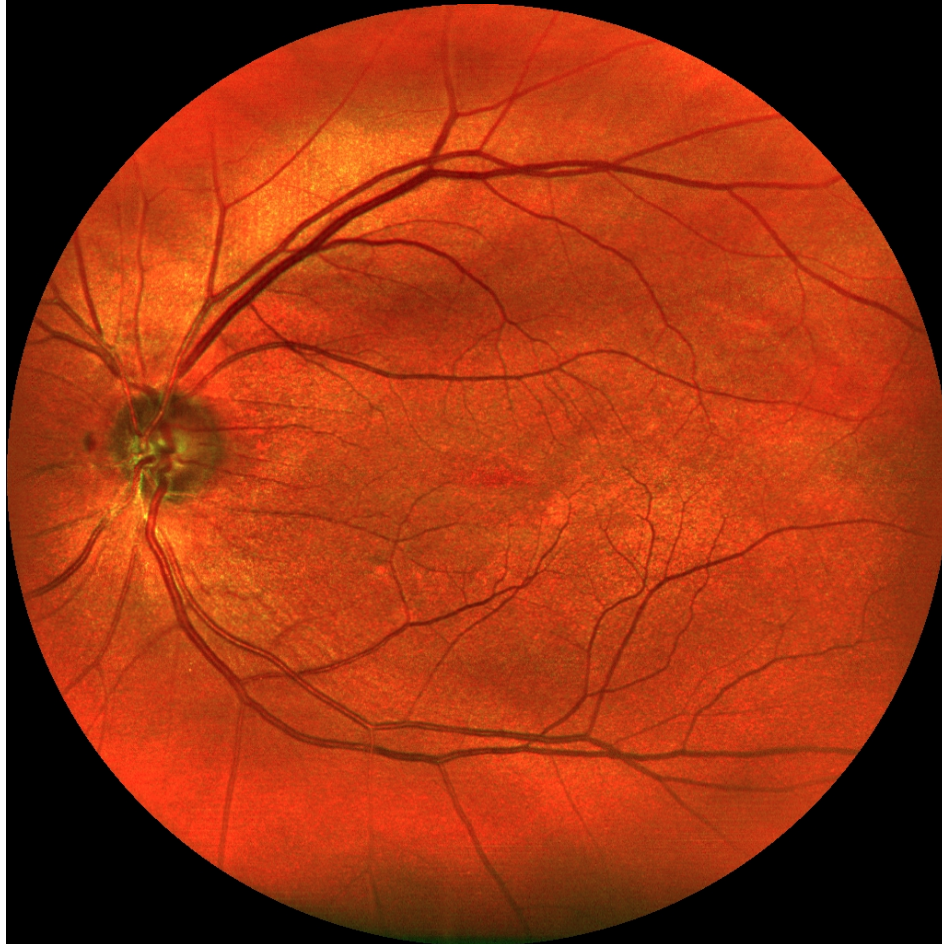Canon green



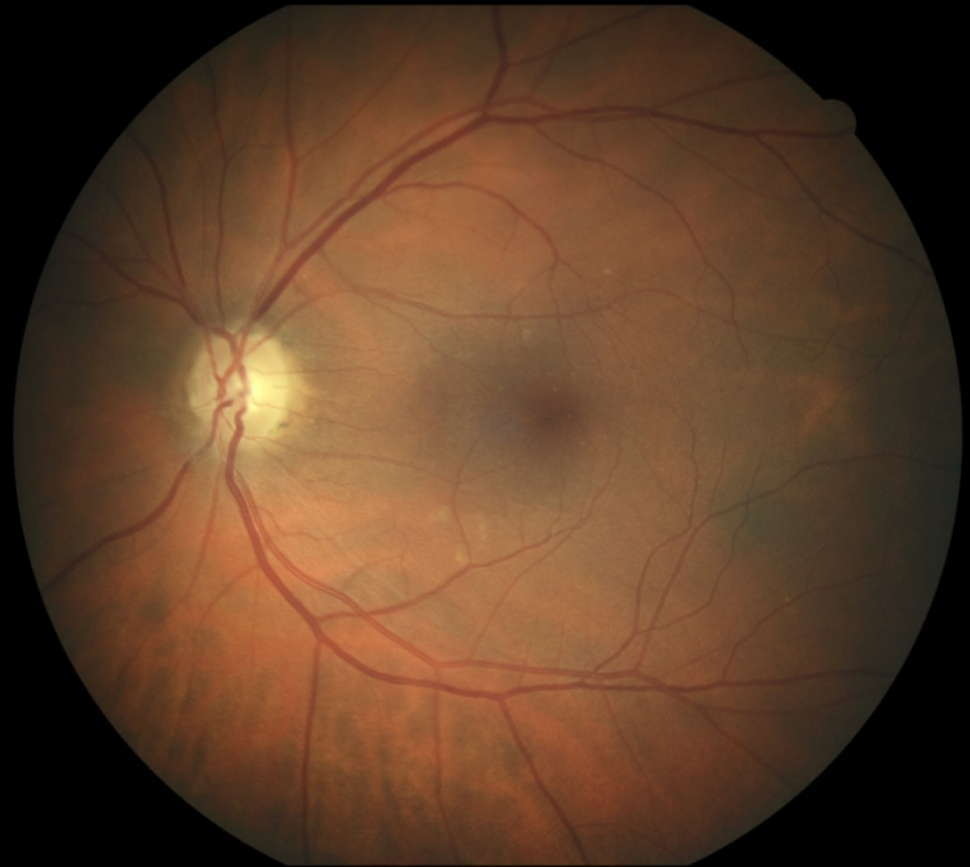

# Female, age 64, glaucoma

EasyScan



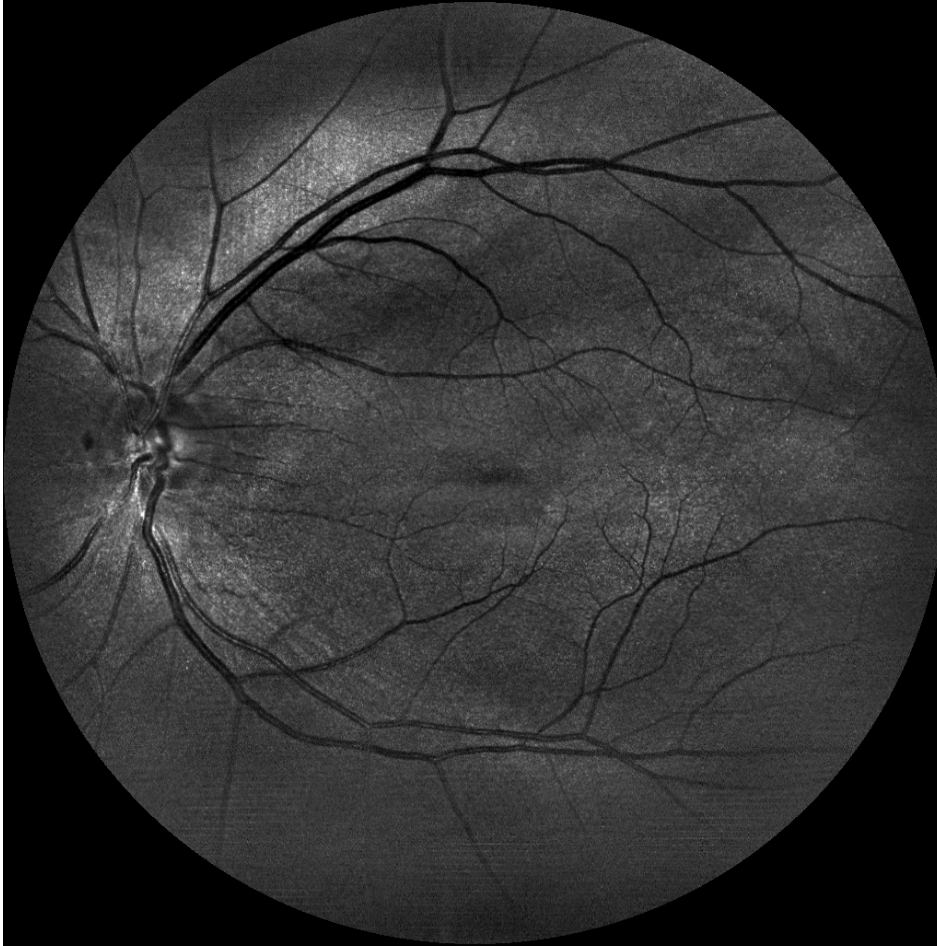
Canon



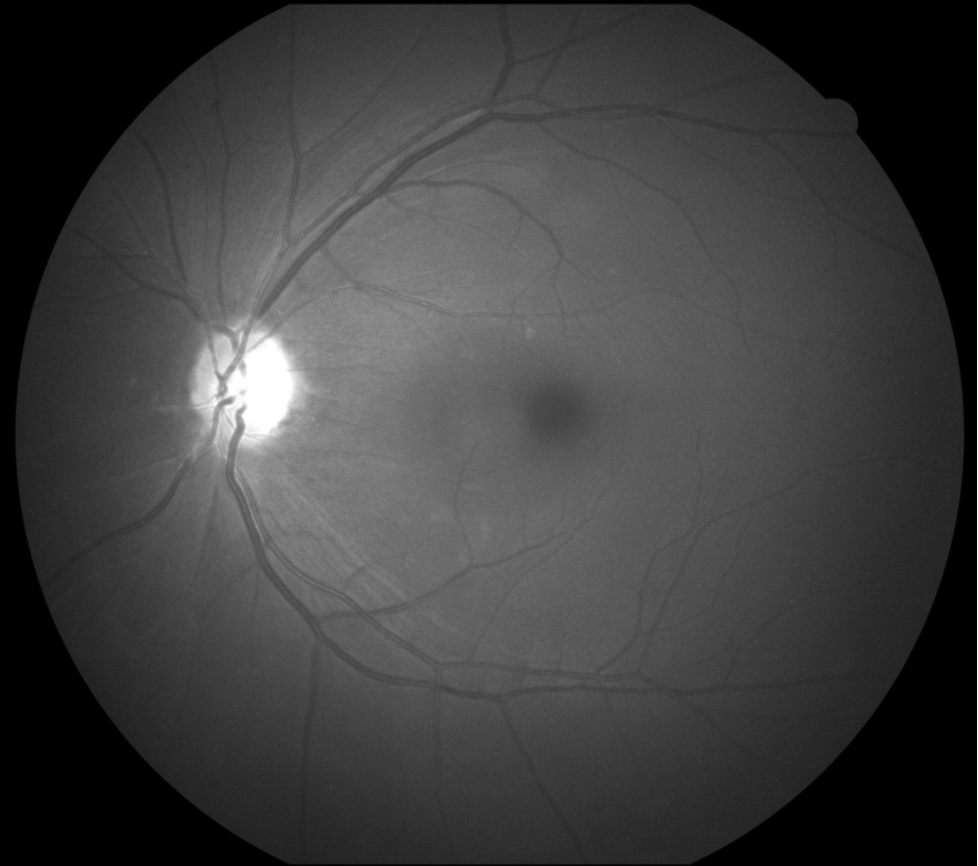


# Female, age 64, glaucoma

EasyScan green

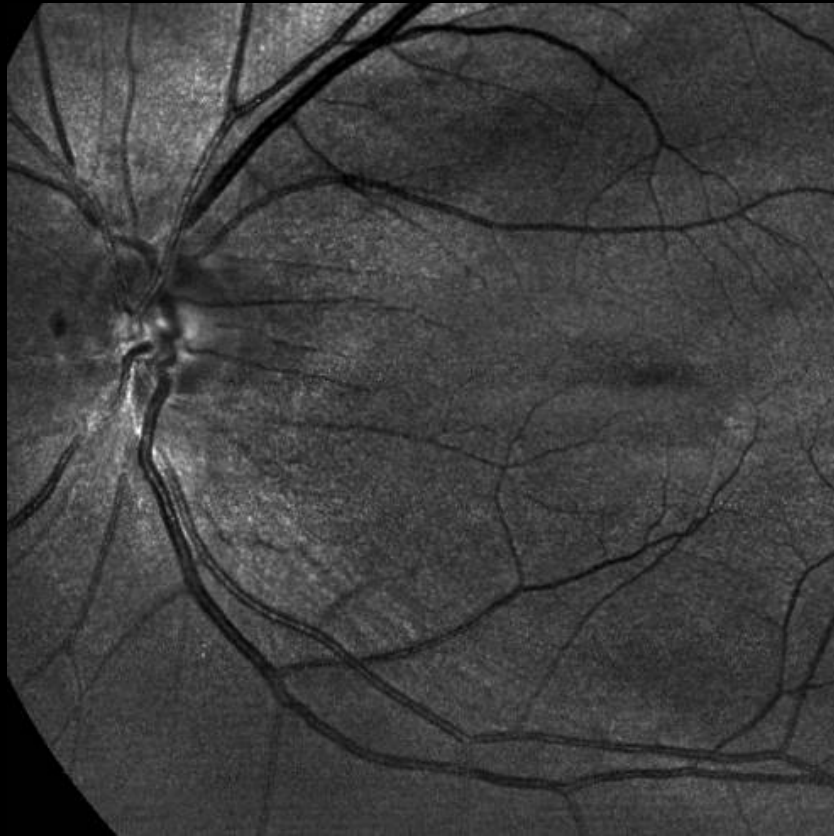

Canon cobalt

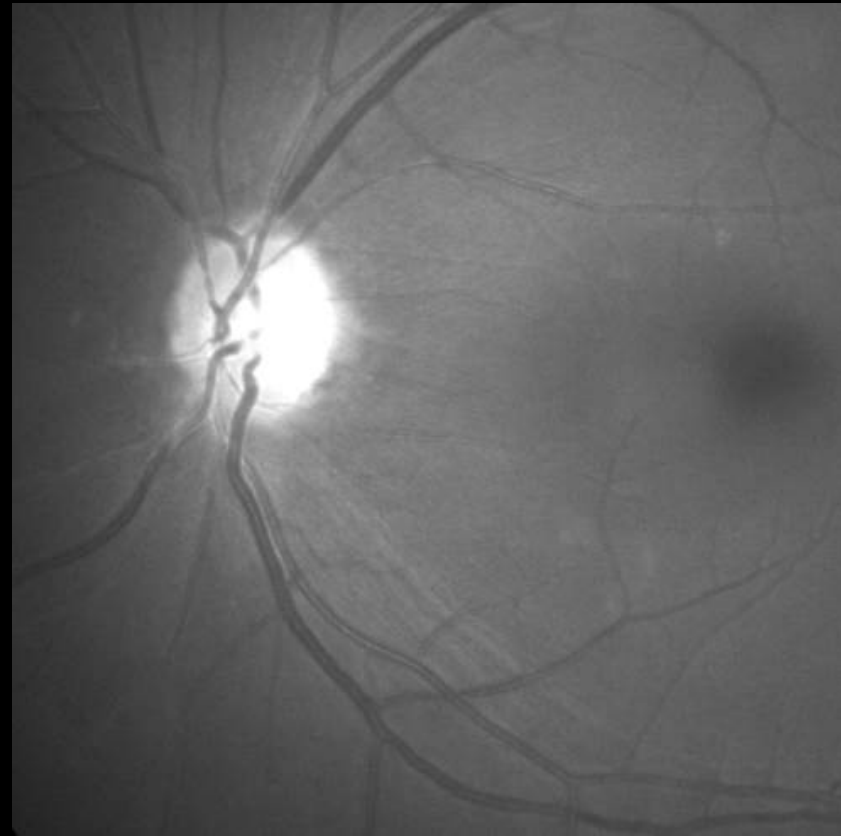


# Female, age 64, glaucoma

EasyScan green

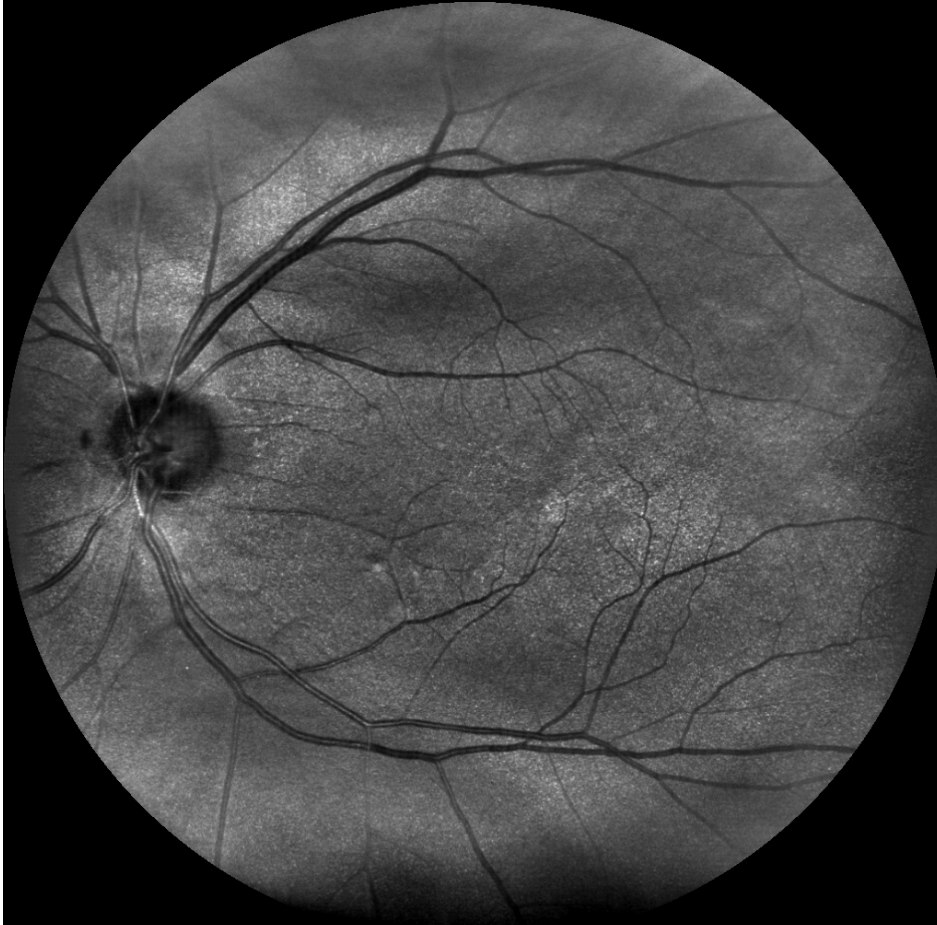

Canon cobalt

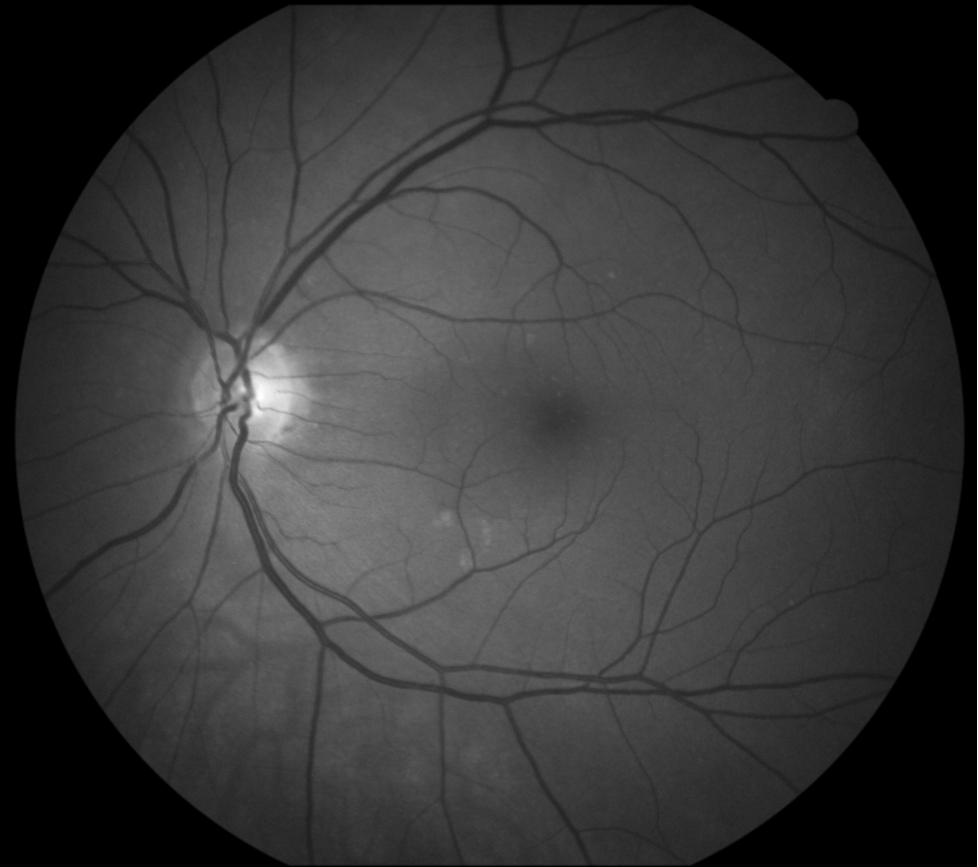


# Female, age 64, glaucoma

EasyScan near infrared



Canon green





# Thank You

- EyeVision Oy, Santtu Oittinen
- i-Optics, Anand Manichand
- Coronaria Eye Clinic, Tilkka Eye Hospital Helsinki
- Photographer Kalle Mustonen